

Comparison of Intralesional Vitamin D with Intralesional Triamcinolone Acetonide in the Treatment of Keloids

Nader Pazyar¹, Sedigheh Sananzadeh^{1*}, Reza Yaghoobi¹, Nima Bakhtiari²

1. Dermatology Department, School of Medicine, Ahvaz Jundishapur University of Medical Sciences, Ahvaz, Iran

2. Pharmacology Department, School of Medicine, Ahvaz Jundishapur University of Medical Sciences, Ahvaz, Iran

ABSTRACT

Background: Hypertrophic scars and keloids are disorders caused by the excessive growth of connective tissue, associated with the accumulation of collagen and cellular matrix components. These scars are caused by abnormal wound healing and can have a great impact on patients' lives. Therefore, we aimed to compare the effect of intralesional injection of vitamin D with triamcinolone acetonide in the treatment of keloid.

Methods: This study was a one-sided blind clinical trial, conducted on 22 patients (44 samples) with keloid. It was a randomized, blinded clinical trial, conducted in Imam Khomeini Hospital in Ahvaz, Iran in 2022. In each group, triamcinolone or vitamin D was injected at the lesion site with an interval of three weeks and an average of 6 sessions. The patients were re-evaluated 3 months after the end of the treatment in terms of recurrence.

Results: By examining the VSS scale in each of the groups, this scale decreased significantly in both groups after the intervention ($P=0.001$), which was greater in the group receiving triamcinolone ($P=0.001$).

Conclusion: It seems that the injection of vitamin D at the site of the lesion helps to treat it, but the effectiveness of the usual triamcinolone treatment was still higher, it is suggested to use vitamin D as an adjunctive treatment in these patients.

KEYWORDS

Colloid; Vitamin D; Triamcinolone

Please cite this paper as:

Pazyar N, Sananzadeh S, Yaghoobi R, Bakhtiari. Comparison of Intralesional Vitamin D with Intralesional Triamcinolone Acetonide in the Treatment of Keloids. *World J Plast Surg.* 2024;13(2):44-52.
doi: 10.61186/wjps.13.2.44

INTRODUCTION

Scar keloid is a relatively common disease that usually occurs due to injuries destructing the skin, and is caused by the excessive production of dense connective tissue that occurs after the healing of skin lesions, as well as in certain breeds, especially it is more common in those with darker skin ¹.

Although the spontaneous formation of keloid has been reported, the common causes of this disease are burns, surgery and trauma ².

Whereas keloid pathophysiology remains still unknown, but various mechanisms are involved in its creation. There is now considerable evidence that keloidogenesis may be induced by multiple systemic factors (such as adolescence, pregnancy, hypertension, and a variety of genetic factors) and local factors (such as anatomical location,

*Corresponding Author:

Sedigheh Sananzadeh

Dermatology Department, School of Medicine, Ahvaz Jundishapur University of Medical Sciences, Ahvaz, Iran

Email: s.sanzadeh@gmail.com

Received: 2/17/2024

Accepted: 7/19/2024

delayed wound healing, wound depth, and most importantly, mechanical forces such as skin tension) which together or alone cause persistent wound inflammation and scarring³.

Clinical findings of this disease are highly variable and depend on the type of skin injury⁴. Keloid size varies from a few millimeter papule to several centimeters⁵. It is often pedunculated in the earlobes, neck and abdomen, while it is prominent and has a smooth surface in the middle of the chest and upper back and extremities⁶. Considering the prominence, consistency, and color of the lesion, keloid can cause cosmetic problems for the patient, and when the lesion is large or located near the joints, it may cause limitation of movement in the joint⁷. Due to keloid resistance to treatment or high recurrence, its treatment is still considered a problem⁸. There are highly variable surgical and non-surgical treatment strategies for hypertrophic and keloid scars available, such as treatment with silicone-based products, intralesional injection of triamcinolone acetonide (TAC), cryotherapy, intralesional verapamil, laser, intralesional antimitotic drugs, radiotherapy, modulating immunity, and botulinum toxins⁹.

Today, intralesional injection has received more attention due to its effectiveness in stimulating cellular immunity. Intralesional injection of triamcinolone acetonide is now the most common treatment way for keloid scars, this therapy is used alone or in combination with 5-fluorouracil (5-FU), verapamil and bleomycin or after surgical resection, and it seems to be the golden standard in non-surgical management of keloid scars. This treatment way has been proven that is effective in reducing the size of hypertrophic scars and keloid, reducing symptoms such as itching and pain, and preventing recurrence¹⁰.

Vitamin D is a fat-soluble vitamin that is obtained by exposure to sunlight, diet, or supplements. Vitamin D has a role in serum calcium homeostasis and inhibition of cell proliferation, enhancement of cell differentiation and apoptosis. Vitamin D, also, is important in the regulation of genes involved in epithelial-to-mesenchymal transition, a process that is effective in cancer fibrosis and metastasis, as well as keloid scarring. Few studies have investigated the effectiveness of vitamin D in the treatment of keloids¹¹. In addition, its therapeutic effect has not been studied in comparison with the intralesional injection of triamcinolone as the gold standard of

treatment.

We aimed to examine the effect of intralesional injection of vitamin D in keloid treatment and compare it with intralesional triamcinolone injection.

MATERIALS AND METHODS

Ethical considerations

This article has been approved by the code of ethics (IR.AJUMS.HGOLESTAN.REC.1401.063) in Ahvaz Jundishapur University of Medical Sciences. It was registered with the code (IRCT20220902055857N1) in the clinical trial registration center of Iran.

This study was a randomized, blinded clinical trial, conducted in Imam Khomeini Hospital in Ahvaz, Iran in 2022. G*power sample size calculation software was used to calculate the sample size in two groups. The number of people for each group, to get the confidence factor of 95% and the test power of 80%, was estimated at least 26 cases (lesions) and a total of 52 lesions was calculated.

Patients with keloid, using random sampling method, were selected and allocated into case and control groups. The simple random division procedure for patients with one lesion was as follows: odd numbers were given to the intervention group (vitamin D) and even numbers were given to the control group (triamcinolone). Then, according to the number of the studied sample, the relevant numbers were written on a card and placed in an envelope, and the envelopes were sealed, then the patient's number was written on each envelope. The envelope related to patient number 1 were given to the first patient who was entered into the study and envelope number 2 were given to the second patient. This way continued until the last participant. Since it was important to maintain randomization, the person who prepared the envelopes was different with someone, which registered the patients and provided them the envelopes. In order to prevention of the doctor's opinion influential on the allocation of the treatment of patients in any special group, the registration process and division the participants into groups was performed by someone other than the doctor.

For patients with two envelope lesions, the given receipt was considered for the upper or right lesion of the patient. The criteria for entering this study was included as following: willingness to participate in the study, both sexes and having the ages 18 to

60 years, all patients have two or more keloids, the duration of lesions should be less than 5 years and without treatment so far, having different types of keloids in different parts of the body with size of 5 cm in greatest dimension.

Exclusion criteria included unwillingness to participate in the study, facial keloids, active infection in or near the keloids, pregnant or lactating women, patients with underlying diseases such as diabetes, mental illness, cancer, and heart disease. After obtaining informed consent from the patients, the lesions of the patients were divided into two groups, case and control. In the case group, intralesional injection of vitamin D was used, the vitamin D ampoule used belonged to Caspin Pharmaceutical Company, and after 3 months from the last treatment session, the patients were examined. An ampoule of vitamin D 300,000 units was injected with a dose of 2 tenths of a milliliter per 1 cm of the lesion. A maximum of one milliliter of vitamin D was injected in each lesion. The injection site was cleaned with an alcohol pad. The procedure in this group was as follows: first, the patient's lesion was examined, and after recording the size, consistency, symptoms, color, and duration of the lesion and the factors causing it, at first lidocaine and then the vitamin D ampoule were injected into the lesion (intralesional injection) using an insulin syringe with a 24-gauge needle and with gentle pressure. The intervals of treatment sessions were once every 3 weeks (an average of six sessions was considered as the duration of the patient's treatment).

The patients were followed-up 3 months after the end of the treatment in terms of recurrence. The lesions were photographed at the end of the sessions. There was also an evaluation based on the Vancouver scar scale and the patients' satisfaction with the treatment, regarding the treatment methods of each of the lesions. This scale is based on 4 criteria of pigmentation, keloid height, vascularity and flexibility/consistency of the lesion. In the control group, the therapeutic method of intralesional injection of triamcinolone from Elixir Company with a concentration of 40 mg/ml (which was considered as 50% concentration equal to 20 mg/ml for the patient) was used in a maximum of six sessions. A maximum of one-milliliter triamcinolone was injected in each lesion once every 3 weeks. Demographic and clinical information such as sex, age, location and size of keloid, family

history, duration of illness and cause were collected by checklist.

Finally, SPSS software version 26 (IBM Corp., Armonk, NY, USA) used to describe quantitative data from mean and standard deviation and to describe qualitative data from frequency tables and graphs. Then, the normality of the quantitative data was checked with the Kolmogorov Smirnov test. Mann-Whitney, Wilcoxon and Chi-square tests were used to analyze the data. Multivariate analyzes were used to compare the level of satisfaction and VSS scale and side effects of intralesional injection of vitamin D with triamcinolone. A significant level of 0.05 was considered for all tests.

RESULTS

Thirty patients were first selected, 8 patients then excluded the study (3 patients due to the large number of sessions and 5 others because of the distance), and finally the information of 22 patients was collected. Ten women (45.45%) and 12 men (54.55%) with the average age of 35.23 ± 8.57 years were examined. The average duration of keloid appearance was 3.09 ± 1.4 years (the minimum time was 1 and the maximum was 5 years). In examining the etiology of keloid in these patients, it was shown that the most common cause was burns (40.91%), followed by wounds and acne (22.73%). In one patient, the keloid was after surgery and in 2 patients, the cause was spontaneous. Investigations also showed that 4 patients (18.18%) had a family history of keloid, but 18 patients (81.82%) had no family history. The location of keloid in two parts of the body in the patients was as follows: 8 patients had lesions in the chest, 6 in the upper limb, 3 in the back, 2 in the neck, 2 in the abdomen, and 1 in the lower limb, and vitamin D was injected for them. In the patients who received triamcinolone, 9 people had lesions on the chest, 7 people on the upper limb, 3 people on the back, and 3 rest of patients had only one lesion in one of the neck, lower limb and abdomen parts.

One of the things examined in this study was the skin type of the patients, which showed that most people (about 68%) had skin type 4, while 22.71% had skin type 3 and 2 people (9.1%) had type 5. In order to investigate the effect of the intervention on the vascularity, height/thickness, consistency and pigment of the colloids, these items were evaluated

before the intervention. The table below shows the results of the chi-square test, which shows that there is no difference between the two lesions. This means that the appearance characteristics of the keloids in both lesions are the same before the intervention and these characteristics do not have a disturbing effect on the effectiveness of the intervention. In general, the results showed that there was no difference in all the items (Table 1).

Wilcoxon test was used to check the value of VSS. The average VSS in the group-receiving vitamin D was 9.05 ± 2.01 and in the group receiving triamcinolone 82.82 ± 1.68 . The *P*-value calculated in this test was equal to 0.63, which is greater than 0.05, indicating no significant difference between the two lesions. The VSS value is the same for both lesions and did not have a disturbing effect on the

effectiveness of the intervention.

The table below shows the comparison results of VSS items after vitamin D and triamcinolone injection. As can be seen, there was a significant difference between the two lesions in terms of height/thickness, consistency and pigment of the colloids. However, in terms of vascularity, there is no difference between the two lesions. Based on the following results, the characteristics of the lesion in the group receiving triamcinolone were better, the height of the keloid in none of the patients in this group was more than 5 mm, the number of people who had flexible keloid was more in this group (60.63%). In addition, hypopigmentation was seen very much in this group (77.30%). After the intervention, the average VSS in the group receiving triamcinolone was 4.59 ± 1.40 , while it was significantly higher in

Table 1: Examining the appearance characteristics of keloids before intervention

| Appearance characteristics | | Vitamin d receptors | Triamcinolone receptors | Statistical value of the chi-square test | <i>p</i> -value |
|----------------------------|-------------------|---------------------|-------------------------|--|-----------------|
| Pigmentation | Normal | 4(18/18) | 2(9/09) | 0.77 | 0.38 |
| | Hyperpigmentation | 18(81/81) | 20(90/90) | | |
| Pliability | Yielding | 2(9/09) | 4(18/18) | 1.52 | 0.46 |
| | Firm | 13(59/09) | 14(63/63) | | |
| | Banding | 7(31/81) | 4(18/18) | | |
| Height | < 2 mm | 1(4/54) | 1(4/54) | 0.42 | 0.80 |
| | < 5 mm | 6(27/27) | 8(36/36) | | |
| | >5mm | 15(68/18) | 13(59/09) | | |
| Vascularity | Normal | 3(13/63) | 1(4/54) | 0.91 | 0.87 |
| | Pink | 8(36/36) | 8(36/36) | | |
| | Red | 5(22/70) | 7(31/81) | | |
| | Purple | 6(27/27) | 6(27/27) | | |

Table 2: Examining the appearance characteristics of colloids after the intervention

| Appearance characteristics | | Vitamin d receiving | Triamcinolone receiving | Statistical value of the chi-square test | <i>p</i> -value |
|----------------------------|-------------------|---------------------|-------------------------|--|-----------------|
| Pigmentation | Normal | 5 (22/70) | 2 (9/10) | 28.08 | 0.00< |
| | Hyperpigmentation | 17 (77/30) | 3 (13/60) | | |
| | Hypopigmentation | 0 (0) | 17 (77/30) | | |
| Pliability | Supple | 3 (13/60) | 14(63/60) | 17.17 | 0.001 |
| | Yielding | 9 (40/90) | 8 (36/40) | | |
| | Firm | 8 (36/40) | 0 (0) | | |
| Height | Banding | 2 (9/10) | 0 (0) | 8.47 | 0.01 |
| | < 2 mm | 10 (45/50) | 16 (27/70) | | |
| | 2- 5 mm | 5 (22/70) | 6 (27/30) | | |
| Vascularity | >5mm | 7 (31/80) | 0 (0) | 2.54 | 0.48 |
| | Normal | 6 (27/30) | 5 (22/70) | | |
| | Pink | 11 (50/00) | 14(63/60) | | |
| | Red | 3 (13/60) | 3 (13/60) | | |
| | Purple | 2 (9/10) | 0 (0) | | |

the group receiving vitamin D and equal to 6.91 ± 2.50 . The *P*-value in this test was less than 0.001, which indicated a statistically significant difference. Therefore, the amount of VSS was lower in keloids that were treated with triamcinolone, and higher in the group receiving vitamin D (Table 2).

Table 3 shows the amount of VSS after injection in both lesions receiving vitamin D and triamcinolone divided by sex, family history, etiology and skin type. This table has two *P*-values, so that the *P*-value* is the intra-group comparison, in the sense that the group receiving vitamin D have been compared regarding gender, family history, skin type and etiology.

From the *P*-value* presented in the table below, it can be concluded that there was no significant difference in the VSS value between different genders, skin types, family history and various causes in the group treated by vitamin D. It is worth mentioning that in surgical etiology, since there was only one person, it

was not possible to calculate the standard deviation. In addition, there was no significant difference for VSS between different genders, skin type, family history and different causes in the group were given triamcinolone injection into the skin lesion.

Based on the results presented in Table 4, there was no significant difference between the amount of VSS in different locations of the lesion and in between any of the treatment methods. According to the *P*-value, no significant difference was found in both methods. It is worth mentioning that it was not possible to calculate the standard deviation in the lower limbs, neck and abdomen because there was only one person.

In general, the comparison of the amount of VSS in each intervention showed a significant reduction the in amount of VSS after the injection; but as shown in Table 5, the reduction of VSS in keloids receiving vitamin D was lower (the reduction value

Table 3: Checking the value of VSS according to the type of intervention and other factors

| | | The amount of VSS in the group receiving vitamin D | The amount of VSS in the group receiving triamcinolone |
|--------------------------|------------------|--|--|
| Sex | Male | 2.51 ± 7.83 | 4.58 ± 1.16 |
| | Female | 2.09 ± 5.80 | 4.60 ± 1.71 |
| | <i>P</i> -value* | 0.97 | 0.056 |
| Family history of keloid | Has | 2.06 ± 8.25 | 5.25 ± 1.70 |
| | Doesn't have | 6.61 ± 2.54 | 4.44 ± 1.33 |
| | <i>P</i> -value* | 0.31 | 0.24 |
| Skin type | Type 3 | 6.00 ± 2.64 | 4.88 ± 1.55 |
| | Type 4 | 7.54 ± 2.36 | 4.62 ± 1.19 |
| | Type 5 | 5.00 ± 1.44 | 4.50 ± 2.12 |
| | <i>P</i> -value* | 0.16 | 0.15 |
| Ethiology | Acne | 6.00 ± 3.00 | 4.80 ± 1.92 |
| | Burning | 6.89 ± 2.20 | 4.56 ± 1.33 |
| | Spontaneously | 8.50 ± 3.53 | 5.00 ± 1.41 |
| | Surgery | 10 | 3 |
| | Wound | 6.60 ± 2.51 | 4.60 ± 1.34 |
| | <i>P</i> -value* | 0.56 | 0.84 |

Table 4: Examination of VSS value by type of intervention and location of lesion

| Locations of the lesion | The amount of vss in the group receiving vitamin d | The amount of vss in the group receiving triamcinolone |
|-------------------------|--|--|
| Upper limbs | 5.33 ± 1.63 | 4.28 ± 1.49 |
| Lower limbs | 5/00 | 3/00 |
| Chest | 8.50 ± 2.56 | 4.88 ± 1.26 |
| Neck | 8.50 ± 2.12 | 3/00 |
| Abdomen | 6.50 ± 0.70 | 4/00 |
| Back | 5.66 ± 3.05 | 5.66 ± 1.52 |
| <i>p</i> -value | 0.15 | 0.41 |

Table 5: Examination of VSS value before and after the intervention

| Intervention type | VSS before the intervention | VSS after the intervention | P-value ** |
|-------------------------|-----------------------------|----------------------------|------------|
| receiving vitamin D | 9.05 ± 2.01 | 6.91 ± 2.50 | 0.001< |
| receiving triamcinolone | 8.82 ± 1.68 | 4.59 ± 1.40 | 0.001< |

was 2.14), while the reduction of VSS in keloids that were injected with triamcinolone was much higher (the reduction value was 4.23).

Figures 1 and 2 show the complications caused by each method.

The results of chi square test to evaluate the level of satisfaction (VRS) showed that there was no change in 4 people who received vitamin D, 3 people had a poor response and only 3 people had a good response to the treatment. While 9 people treating with triamcinolone had received a good response. This distinguish between the two received interventions had a statistically significant difference ($P<007$) (Figure 3).

DISCUSSION

Hypertrophic scar and keloid are caused by abnormal wound healing. The mechanisms that seems to be underlying the pathogenesis of keloids are included excessive inflammation, excessive angiogenesis, and delayed apoptosis of fibrotic myofibroblasts. Vitamin D has a positive effect in reducing the progression of tissue fibrosis.

In this study, 22 people with two keloid lesions (44 lesions in total) were examined. As the results showed, after the intervention, there was no significant difference between the two groups in

terms of vascularity, but the characteristics of the lesion in the group receiving triamcinolone had better conditions, so that the height of the keloid in none of the patients in this group was not more than 5 mm. The number of people with flexible keloid (60.63%) and hypopigmentation (77.30%) were more in this group. These differences were significant in comparison to the group receiving vitamin D. After the intervention, the average VSS in the group receiving triamcinolone was 4.59 ± 1.40 , while it was significantly higher in the group receiving vitamin D (6.91 ± 2.50), which indicated the greater effectiveness of injectable triamcinolone compared to the group receiving injectable vitamin D. The results also showed that in the group receiving triamcinolone, the level of satisfaction was significantly better than the other group (Fig. 4 and 5).

Our findings are consistent with the study by Zhang et al., which provide a logical way to test vitamin D supplementation as a preventive and/or initial treatment strategy for keloid and related fibrotic disorders¹¹. They also investigated the effect of 1,25-dihydroxyvitamin D3 (1,25D) in the pathogenesis of tissue fibrosis by keloidal fibroblasts (KFs) and reported that 1,25D inhibited cell proliferation of keloidal fibroblasts. Their hypothesis was that vitamin D affects profibrogenic processes by targeting normal fibroblasts and KF¹¹. In addition,

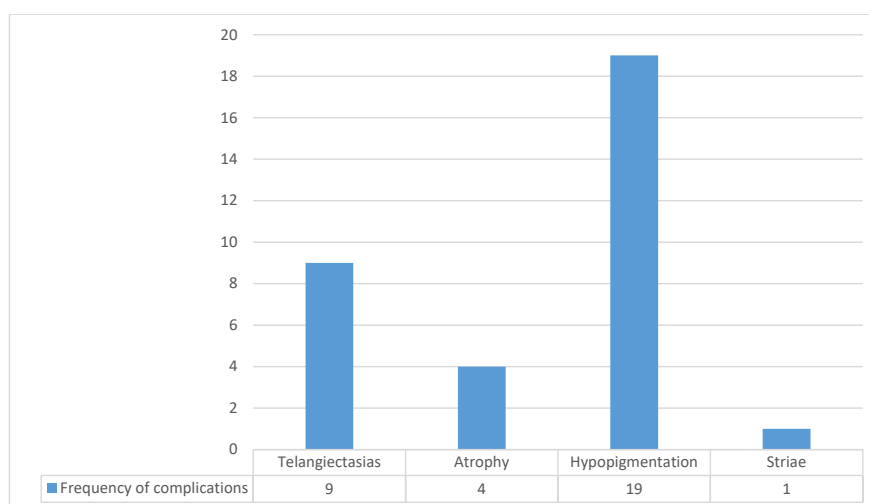


Figure 1: Side effects of Triamcinolone injection

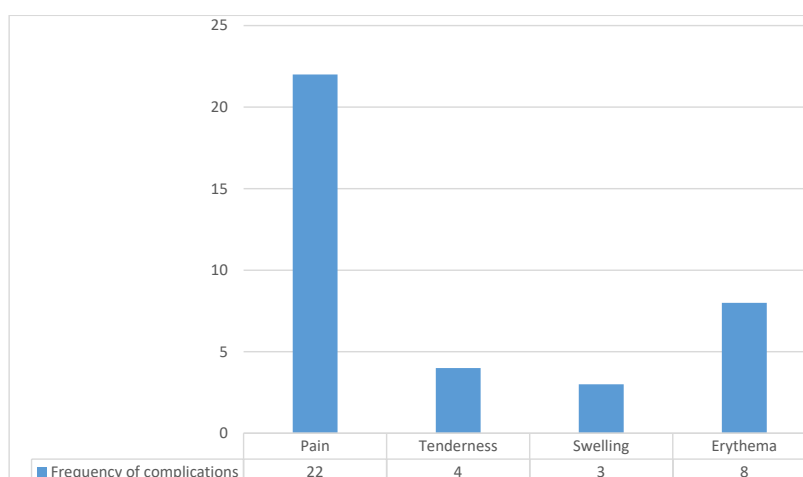


Figure 2: Side effects of vitamin D injection

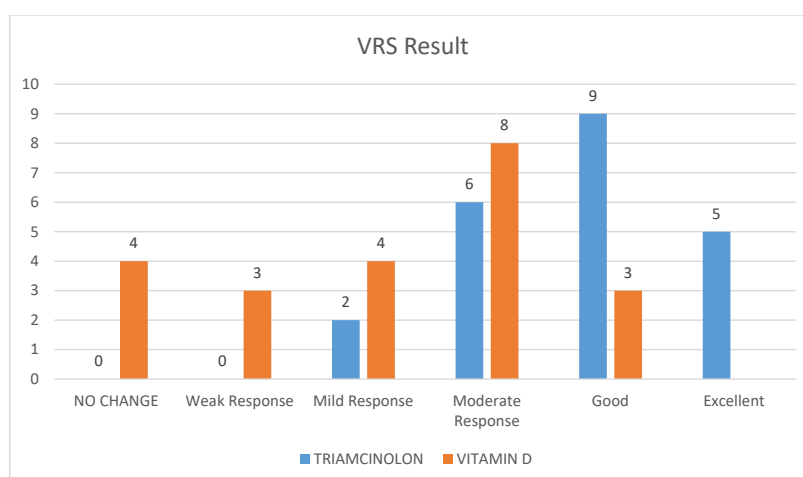


Figure 3: The level of patient satisfaction according to the intervention received

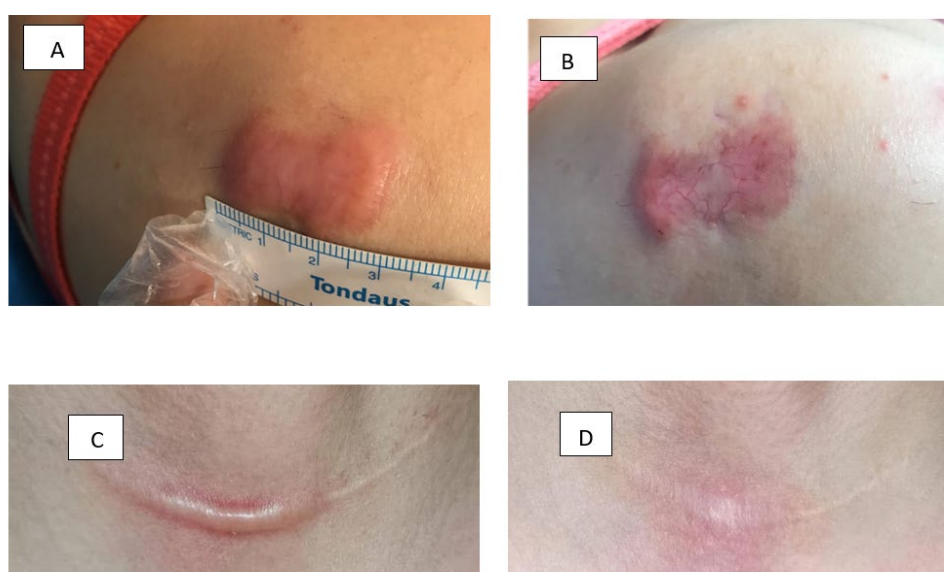


Figure 4: Before treatment with Triamcinolone (A), after treatment with Triamcinolone (B), before treatment with Vitamin D (C), and after treatment with Vitamin D (D)

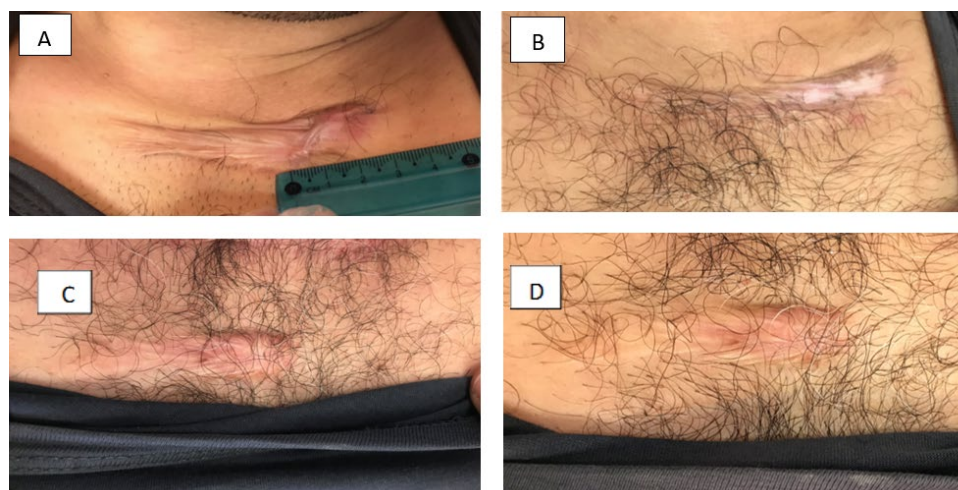

Figure 5: Before treatment with Triamcinolone (A), after treatment with Triamcinolone (B), before treatment with Vitamin D (C), and after treatment with Vitamin D (D)

vitamin D inhibits mesenchymal pluripotent cells and primary lung fibroblasts by regulating genes related to apoptosis. Also, vitamin D has been implicated in other anti-fibrotic key factors that provide an insight into the possible mechanism of inducing an anti-fibrotic phenotype by vitamin D¹². Our results are consistent with the study by Damanik et al., who reported that the active form of vitamin D prevents the proliferation of keloid fibroblasts. They concluded that the lower the serum level of 25-hydroxyvitamin D, the more severe the degree of keloid. They also perceived that there is no significant relationship between the serum level of 25-hydroxyvitamin D and gender, age, duration of keloid and family history¹³.

The only clinical trial conducted on the therapeutic effect of vitamin D on keloids is the study by Mamdouh et al., who examined 40 individuals with keloid lesions aged 18 to 56 years and reported that weekly injections of 0.2 mL of vitamin D with 200,000 IU per centimeter of the lesion for a maximum of 4 weeks reduces the height, pigmentation and elasticity of the lesion, which was consistent with our study. The aforementioned study reported a decrease in vascularity, which was contrary to the results of our study¹⁴. Also, in Ahuja's study, which investigated the comparative effect of intralesional verapamil hydrochloride and triamcinolone acetate in the treatment of hypertrophic and keloid scars, the effectiveness of triamcinolone was reported to be faster and better, and in the present study, the effectiveness of triamcinolone was better than vitamin D¹⁵.

The most common skin type was Fitzpatrick's phototype IV and the most common region involved was the chest, which was consistent with our study¹⁵.

Regarding the complications of vitamin D treatment, the most common complication in our study was related to post-injection pain, which is consistent with Mamdouh's study, which reported post-injection pain and tenderness in 52% of patients. He reported that most of these complications were resolved by the day after the injection¹⁴. In most studies, pain after injection was the most common complication caused by vitamin D injection.

CONCLUSION

Vitamin D plays an effective role in the treatment of keloids. Vitamin D injection can be considered as a cheap and safe treatment method. In return, the therapeutic effect of triamcinolone was better than vitamin D injection, which approves the usual treatment to be more effective. However, it is suggested to conduct clinical trials with a larger sample size and a longer intervention period. It is also suggested that future studies examine the effects of treatment on other skin types so that we can talk more confidently about the effectiveness of treatment methods. In addition, more studies are needed in the field of better understanding of the mechanisms that cause excessive scarring for the development of effective methods and strategies in prevention and treatment.

ACKNOWLEDGMENTS

This article is derived from a research project with the number (U-01068) that was carried out with the financial support of the Research and Technology Vice-Chancellor of Jundishapur University of Medical Sciences.

We would like to express our gratitude to the Vice-Chancellor of Research and Technology of Jundishapur University of Medical Sciences and Health Services for their material and spiritual support and to the patients who cooperated with us in conducting this study.

CONFLICT OF INTEREST

The authors declare that there is no conflict of interest for this article.

REFERENCES

1. Naeini FF, Najafian J, Ahmadpour K. Bleomycin tattooing as a promising therapeutic modality in large keloids and hypertrophic scars. *Dermatol Surg* 2006;**32**(8):1023-30.
2. Shaldoum DR, Hassan GF, El Maadawy EH, El-Maghraby GM. Comparative clinical study of the efficacy of intralesional MMR vaccine vs intralesional vitamin D injection in treatment of warts. *J Cosmet Dermatol* 2020;**19**(8):2033-40.
3. El Sayed MH, Sayed FS, Afify AA. Intralesional zinc sulfate 2% vs intralesional vitamin D in plantar warts: A clinicodermoscopic study. *Dermatol Ther* 2020;**33**(3):e13308.
4. Kelemen O, Kollár L. Current methods of treatment and prevention of pathologic scars. *Magy Seb* 2007;**60**(2):63-70.
5. Ledon JA, Savas J, Franca K, Chacon A, Nouri K. Intralesional treatment for keloids and hypertrophic scars: a review. *Dermatol Surg* 2013;**39**(12):1745-57.
6. Draaijers LJ, Tempelman FR, Botman YA, Tuinebreijer WE, Middelkoop E, Kreis RW, et al. The patient and observer scar assessment scale: a reliable and feasible tool for scar evaluation. *Plast Reconstr Surg* 2004;**113**(7):1960-5.
7. Gauglitz GG, Korting HC, Pavicic T, Ruzicka T, Jeschke MG. Hypertrophic scarring and keloids: pathomechanisms and current and emerging treatment strategies. *Mol Med* 2011;**17**(1):113-25.
8. Shaffer JJ, Taylor SC, Cook-Bolden F. Keloidal scars: a review with a critical look at therapeutic options. *JAAD* 2002;**46**(2):S63-S97.
9. Saray Y, Güleç AT. Treatment of keloids and hypertrophic scars with dermojet injections of bleomycin: a preliminary study. *Int J Dermatol* 2005;**44**(9):777-84.
10. Wang R, Mao Y, Zhang Z, Li Z, Chen J, Cen Y. Role of verapamil in preventing and treating hypertrophic scars and keloids. *Int Wound J* 2016;**13**(4):461-8.
11. Zhang GY, Cheng T, Luan Q, Liao T, Nie CL, Zheng X, et al. Vitamin D: a novel therapeutic approach for keloid, an in vitro analysis. *Br J Dermatol* 2011;**164**:729-37.
12. Ramirez AM, Wongtrakool C, Welch T, Steinmeyer A, Zügel U, Roman J. Vitamin D inhibition of pro-fibrotic effects of transforming growth factor β 1 in lung fibroblasts and epithelial cells. *JSBBEZ* 2010;**118**(3):142-50.
13. Damanik VI, Putra IB, Ginting O. Correlation between serum 25-hydroxyvitamin D levels with keloid severity. *Maced J Med Sci* 2019;**7**(1):65.
14. Mamdouh M, Omar GA, Hafiz HS, Ali SM. Role of vitamin D in treatment of keloid. *J Cosmet Dermatol* 2022;**21**(1):331-6.
15. Ahuja RB, Chatterjee P. Comparative efficacy of intralesional verapamil hydrochloride and triamcinolone acetonide in hypertrophic scars and keloids. *Burns* 2014;**40**(4):583-8.