

Effect of Tendon Wrapping with Amniotic Membrane on Zone 6 Extensor Tendon Repair Outcomes

Seyed Esmail Hassanpour ¹, Masoud Yavari ², Seyed Mehdi Moosavizadeh ¹,
Khalil Rostami ¹, Hojjat Layegh ^{3*}

1. Department of Plastic Surgery, Panzdahe Khordad Hospital, School of Medicine, Shahid Beheshti University of Medical Sciences, Tehran, Iran
2. Department of Hand and Microsurgery, Panzdahe Khordad Hospital, School of Medicine, Shahid Beheshti University of Medical Sciences, Tehran, Iran
3. Department of Plastic Surgery, Shahid Modarres Hospital, School of Medicine, Shahid Beheshti University of Medical Sciences, Tehran, Iran

ABSTRACT

Background: Extensor tendon repair is prone to adhesion that affects the outcomes of tendon repair surgery and tendon function regain. Prevention of these complications should be considered in tendon rupture treatment. We aimed to evaluate the effect of tendon wrapping with amniotic membrane on the outcomes of extensor tendon repair in zone 6.

Methods: This randomized controlled clinical trial was conducted on 30 patients with an extensor tendon injury in zone 6 following penetrating trauma to extensor digitorum communis of the third and fourth digits referred to 15 Khordad Hospital, Shahid Beheshti University of Medical Sciences, Tehran, Iran. Patients were randomly assigned into two matched groups based on age and gender. Both groups underwent tendon repair using the modified Kessler method. In the intervention group (n=15), the repair site was wrapped with an amniotic membrane, while the control group underwent the traditional procedure without wrapping. Both groups underwent a similar rehabilitation process. Patients were followed up for 6 months. The QuickDash score, range of motion (ROM), complications, and recovery duration were recorded for patients in both groups.

Results: The patients in the intervention group had a lower QuickDash score ($P<0.001$), ROM ($P<0.001$), and shorter recovery duration ($P<0.001$) compared to the control group. The only complication was a wound infection that was seen in one patient in the control group. There was no evidence of tendon re-rupture and amniotic membrane hypersensitivity among patients.

Conclusion: Amniotic wrapping is an effective method in extensor tendon repair and is associated with better outcomes and faster recovery, suggesting less peritendinous fibrosis.

KEYWORDS

Amniotic membrane; Extensor tendon repair; Adhesion; Functional recovery

*Corresponding Author:

Hojjat Layegh

Department of Plastic Surgery,
Shahid Modarres Hospital, School
of Medicine, Shahid Beheshti
University of Medical Sciences,
Tehran, Iran.

Email: layeghhojjat@gmail.com,
layeghhojjat@sbmu.ac.ir

Received: 11/14/2024

Accepted: 3/23/2025

Please cite this paper as:

Hassanpour SE, Yavari M, Moosavizadeh SM, Rostami K, Layegh H. Effect of Tendon Wrapping with Amniotic Membrane on Zone 6 Extensor Tendon Repair Outcomes. *World J Plast Surg.* 2025;14(1):72-78.
doi: 10.61186/wjps.14.1.72

INTRODUCTION

The incidence of tendon injuries has risen due to the industrial development of societies. More than 320,000 tendon injuries occur following trauma in the United States. New strategies have been developed to strengthen tendon repair. Stem cells, including tendon-derived stem cells (TDSC) and human mesenchymal stem cells (HMSC), growth

factors, including platelet-rich plasma (PRP), and biomaterials, including collagen fiber implants and type 1 collagen sponge are among these strategies¹⁻³. Tendon adhesion to the surrounding tissues is the most common complication after tendon repair⁴. Treatment of flexor tendon injuries is frequently simpler than extensor tendons. The extensor apparatus includes thin surface structures that are very close to the underlying bone. This makes them prone to severe adhesions. Due to their thin skin covering, extensor tendons are at higher risk for injuries even after minor traumas. Early mobilization with a dynamic splint is indicated to reduce postoperative adhesions. Loss of flexion is reported more than loss of extension^{5,6}.

Various methods, including suture technique improvement, early postoperative rehabilitation, and medical prevention of inflammatory response, have been suggested to prevent tendon adhesions. Furthermore, chemical agents and physical barriers have been proposed to prevent adhesion. However, although non-biological elements, including absorbable polymer compounds, prevent adhesion, they can impair tendon blood supply and cause tendon necrosis. These drawbacks have shifted the focus of researchers toward biological membranes, including amniotic membranes⁶⁻¹⁰.

The amniotic membrane is a barrier that can have analgesic properties. This membrane is a non-immunological material that can promote epithelialization and inhibits fibrosis and scarring. Furthermore, the amniotic membrane has anti-inflammatory and anti-bacterial activities and can regulate angiogenesis¹¹. Amniotic epithelial and mesenchymal cells contain regulatory media that leads to cell proliferation, differentiation, and epithelialization; and can inhibit fibrosis, immune rejection, inflammation, and bacterial invasion¹². Due to these properties, the amniotic membrane has been used in many clinical conditions, including burns, chronic wounds, dura defect, intra-abdominal adhesions, peritoneum reconstruction, genital reconstruction, hip arthroplasty, tendon, and nerve repair; microvascular, corneal, intraoral, nasal lining, and tympanic membrane reconstruction^{2,13}.

Although promising properties have been hypothesized for the use of amniotic membrane wrapping in tendon repair, the results of previous studies have been controversial. While the majority

of studies indicated that the use of amniotic membrane wrapping improved range of motion (ROM), pain, and tendon glide while reducing complications¹⁴, other studies indicated no benefits for amniotic membrane wrapping in tendon repair compared to controls or poly D lactic acid^{4,15}. Therefore, we aimed to investigate the effect of using amniotic membrane wrapping in tendon repair in the 6th extensor zone on the outcomes of tendon repair.

METHODS

Study design

This study was a randomized controlled clinical trial that was conducted on patients with zone 6 extensor injuries due to penetrating trauma to extensor digitorum communis (EDC) of the third and fourth digits referred to the 15 Khordad Hospital, Shahid Beheshti University of Medical Sciences, Tehran, Iran.

The study was approved by the Ethics Committee of the Shahid Beheshti University of Medical Sciences (Code IR.SBMU.MSP.REC.1401.049) and was registered in the Iranian Registry of Clinical Trials (Registration number: IRCT20110522006552N2).

Study population

The sample size was calculated based on the findings of a previous study and considering type I and II errors of 5% and 20%, respectively¹⁵. The sample size was 25 patients in each group, increased to 30 patients in each group considering 10% dropout.

Patient selection was performed based on convenience sampling among patients who were candidates for extensor tendon repair. Selected patients were briefed about the procedure and objectives of the study. Written informed consent was signed by all participants in the study. The inclusion criteria were tendon injury in zone 6 of the extensor tendon due to penetrating trauma and willingness to participate in the study. Patients with a history of laceration or previous tendon repair in the upper limb, those with injury in the first, second, and fifth extensor digitorum communis (EDC) tendons, history of immune suppression or allergy, and those who refused to continue the study at any point were excluded from the study.

Randomization

Patients were randomly assigned to intervention or control groups using random block sampling. Patients were assigned to study groups consecutively using a predefined block size of four to match groups based on age group and gender.

Study interventions

Both the intervention and control group patients received local anesthesia and intravenous sedation. Tendon repair was performed after applying a tourniquet. Tendon rupture was repaired using the modified Kessler method. Core and peritendinous running sutures were performed with 4.0 and 5.0 nylon threads, respectively.

In the intervention group patients (n=15), a 3x3cm sterile acellular amniotic membrane with a thickness of 0.3 mm to 0.5 mm cover (Parsa Teb Company, ir) was used at the repair site at the end of the procedure (Figures 1,2). Prior to application, the infectious serological tests including; VDRL, HCV Ab, HBS Ag, HBS Ab, HIV Ab, HTLV 1,2Ab,

and bacterial tests were performed on all amniotic membranes. Splint was placed at the flexor level of the limb with the wrist at 40 degrees extension, metacarpophalangeal (MP) at 30 degrees flexion, and interphalangeal (IP) joints in extension to allow for IP joint movements. In the control group (n=15), the repair procedure was performed similarly to the intervention group except for amniotic membrane wrapping. All operations were performed by one plastic surgeon who specialized in hand surgery. Similar rehabilitation was performed for both groups. Sutures were removed 10 d after surgery. The wound was covered with a light dressing under the splint until the splint was removed. Patients received first-generation cephalosporin antibiotics for three d after the surgery. Early mobilization was initiated on the second day after the surgery according to the reverse Washington/reverse Kleinert method. Passive extension and active flexion exercises were performed ten times an hour for four weeks. The splint was removed after 4 wk allowing active movements. Therefore, patients underwent 20 sessions of physiotherapy with TEN, IR, US, ROM, and EXERCISE and were followed up for 6 months.




Figure 1: Sterile amniotic membrane

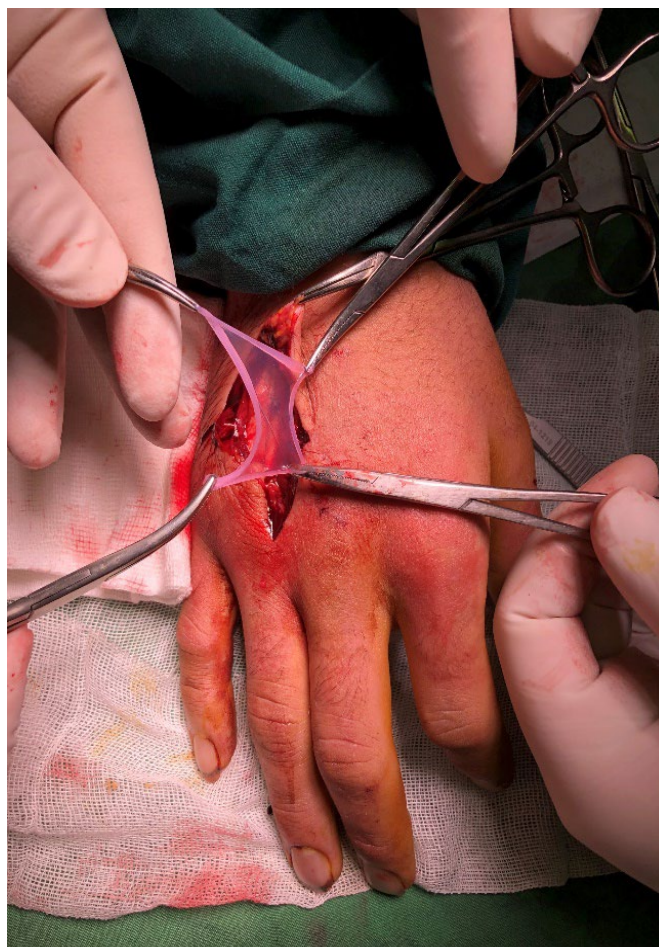


Figure 2: Clinical photo of extensor tendon wrapping with amniotic membrane after tendon repair using the modified Kessler method

Measurements

Tendon recovery duration, metacarpophalangeal (MP), proximal interphalangeal (PIP), distal interphalangeal (DIP) range of motion (ROM), total active motion (TAM), and complications, including infection, tendon re-rupture, and functional capacity using the QuickDASH (disabilities of the arm, shoulder, and hand) standard score questionnaire were evaluated and recorded for patients in both groups.

Statistical analysis

Descriptive statistics, including mean and standard deviation for normally distributed quantitative variables, median and interquartile range (IQR) for non-normally distributed quantitative variables, and frequency and frequency percentage for qualitative variables, were used in this study. The Shapiro-Wilks test was used to assess the normality of

quantitative variables. Chi-square or Fisher's exact test was used to examine the relationship between qualitative variables. An Independent t-test was used to compare the mean of normally distributed quantitative variables, while the Mann-Whitney test was used to compare the median of non-normally distributed variables. All statistical tests were performed using the R software considering $P < 0.05$ as a statistically significant level.

RESULTS

This study was conducted on 30 patients in the intervention ($n=15$) and control ($n=15$) groups. A comparison of the baseline characteristics of the patients is presented in Table 1. There was no significant difference in mean age and the distribution pattern of gender, hand dominance, smoking, and repaired tendon between the intervention and control groups ($P > 0.05$). A comparison of the study outcomes is presented

Table 1: Comparison of the baseline characteristics between the intervention and control groups

Variable		Intervention n=15	Control n=15	P
Age(yr)		27.60 ± 8.23	30.13 ± 10.86	0.478†
Gender	Female	3 (20.0%)	1 (6.67%)	0.598‡
	Male	12 (80.0%)	14 (93.33%)	
Dominant hand	Right	13 (86.67%)	11 (73.33%)	0.651‡
	Left	2 (13.33%)	4 (26.67%)	
Smoking		4 (26.67%)	2 (13.33%)	0.651‡
Repaired tendon	EDC 4	9 (60.0%)	10 (66.67%)	>0.999†
	EDC 3	6 (40.0%)	5 (33.33%)	

EDC: Extensor Digitorum Communis

† Mean and standard deviation were presented and the independent t-test was used for the comparison.

‡ Frequency and percentage were presented and the Fisher's exact test was used.

† Frequency and percentage were presented and the chi-square test was used.

Table 2: Comparison of the study outcomes between the intervention and control groups

Variable		Intervention n=15	Control n=15	P
QuickDash score		2.3 (5.65)	20.5 (13.60)	<0.001*†
ROM (TAM)		234.87 ± 15.45	172.80 ± 29.64	<0.001*‡
ROM	MP	82.0 (7.50)	75.0 (7.0)	<0.001*†
	PIP	105.0 (8.0)	86.0 (8.0)	<0.001*†
	DIP	53.0 (4.0)	25.0 (12.0)	<0.001*†
Motion return duration		5.13 ± 0.83	7.60 ± 1.06	<0.001*‡

ROM: Range of Motion, TAM: Total Active Motion, MP: Metacarpophalangeal, PIP: Proximal Interphalangeal, DIP: Distal Interphalangeal

† Median and interquartile range (IQR) were used and Mann-Whitney test was used for the comparison.

‡ Mean and standard deviation were presented and the independent t-test was used for the comparison.

* Significant difference

in Table 2. There was a significant difference in QuickDash score, ROM in TAM, MP, PIP, and DIP joints; as well as motion return duration between the intervention and control groups ($P < 0.001$ each). The median QuickDash scores in patients in the intervention group were significantly lower compared to the control group patients, while the ROM in the affected EDC joint, MP, PIP, and DIP joints were significantly higher among patients in the intervention group compared to those in the control group. Furthermore, the duration of motion return was shorter among patients in the intervention group compared to those in the control group. None of the patients in either group had tendon re-rupture or presented signs and symptoms of hypersensitivity to the human amniotic membrane. Wound infection was the only complication and was observed in one patient in the control group. There was no significant difference between the intervention and control groups in terms of wound infection ($P > 0.999$).

DISCUSSION

The human amniotic membrane is the innermost layer close to the amniotic fluid and fetus. The amniotic membrane contains mesenchymal stem cells. These cells can differentiate into transplanted tissue cells. Amniotic mesenchymal cells can differentiate into keratinocytes (skin epidermis) and induce angiogenesis, myogenesis, and neural regeneration^{16, 17}. Furthermore, the human amniotic membrane has various biological properties, including anti-adhesion, antibacterial, low immunogenicity, anti-inflammatory and anti-scar, and can accelerate tissue repair by producing growth factors¹⁸. The amniotic membrane also has a low preparation and maintenance cost¹⁹. This study was conducted to investigate the effects of using an amniotic membrane on the outcomes of zone 6 extensor tendon repair.

This study showed that patients who received tendon repair with amniotic membrane had a lower

QuickDash score, which indicates better functional ability, compared to the patients in the control group. Furthermore, patients in the intervention group had more ROM (TAM, MP, PIP, DIP) and the duration of return of movements was shorter in them. Regarding the complications, only one patient in the control group had wound infection, while tendon re-rupture was not observed in any group. There was no evidence of sensitivity to amniotic membranes in any of the patients.

In a previous animal study, the role of amniotic membranes in preventing adhesion after flexor tendon repair in zone 2 was investigated in chickens. In the control group, the flexor tendon sheet was removed and the tendon was repaired. In the second group, the FDP tendon and sheet were both repaired. In the third group, the repaired tendon was covered with an amniotic membrane. Histological evaluation of the tendon indicated that the use of an amniotic membrane significantly decreased adhesion compared to other groups, which was consistent with the findings of our study²⁰.

A study on 10 patients with flexor tendon injury repair and amniotic membrane fixation around the tendon showed that unfavorable results in terms of finger ROM, infection, and repair failure were seen in five patients and extensive stiffness requiring joint release and tenolysis was seen in one patient after 6 months follow up. In one patient, the repair failed, and in the other three patients, favorable to good results were reported. The use of an amniotic membrane did not lead to better outcomes compared to the usual tendon repair technique. However, it was unclear whether these adverse results were related to technical factors, the amniotic membrane itself, or the small sample size¹⁵.

In another study in America, a combination of collagen-glycosaminoglycan (CG) biomaterial scaffold and amniotic membrane matrix was used to modify the inflammatory response and create a steady state to improve tendon regeneration. The amniotic membrane was a potent resource for tendon rapping due to its immunomodulatory properties. Considering the observed mechanical efficiency, the authors suggested an amniotic membrane as a prominent biomaterial to strengthen tendon generation¹². This finding was compatible with our study results.

Another study on 89 patients with a flexor tendon injury in zone 2, including tendon repair with

POLY D LACTIC ACID (PDLLA) in 35 patients and human amniotic membrane in 33 patients and 21 patients as a control group, reported that TAM was significantly different in both groups compared to the control group; however, there was no significant difference in TAM between PDLLA and amniotic membrane groups. The incidence of complications, erythema, edema, rupture of tendon, exudate, and pruritis in the control and PDLLA groups were significantly higher than in the human amniotic membrane group⁴. In our study, TAM was significantly better improved in the amniotic membrane groups compared to the control group, which was consistent with the findings of the mentioned study. However, the findings of our study and the mentioned study differed in terms of complications. The reason for this difference might be attributed to the small sample size in our study and the use of different tendons between the studies. Similarly, a study on 19 patients with flexor tendon injury repair, including human amniotic membrane in 9 patients and 10 patients as the control group, reported that pain, tendon glide, and TAM were significantly improved in the human amniotic membrane group compared to the control group, while inflammatory mediators, including interleukin 6 (IL-6) and tumor growth factor B1 (TGF B1), were significantly reduced in contrast to the control group patients who experienced increased inflammatory markers¹.

The limitations of the study included a restricted number of participants in the groups and follow-up of many patients especially during covid 19 pandemic. Therefore, it is suggested that larger multicenter studies evaluate the effects of human amniotic membrane wrapping on the outcomes of tendon repair.

CONCLUSION

Human amniotic membrane wrapping is effective in the process of extensor tendon repair and tendon function recovery. Using amniotic membrane wrapping is associated with better and faster recovery. Functionally, the improved return of motor symptoms, QuickDash Score, and better ROM were obtained, suggesting less peritendinous fibrosis. Therefore, human amniotic membrane wrapping can be used to improve the outcomes of extensor tendon repair.

CONFLICT OF INTEREST

The authors declare that there is no conflict of interests.

REFERENCES

1. Prakash S, Kalra P, Dhal A. Flexor tendon repair with amniotic membrane. *Int Orthop* 2020;**44**:2037-45.
2. Wu F, Nerlich M, Docheva D. Tendon injuries: Basic science and new repair proposals. *EFORT open reviews* 2017;**2**(7):332.
3. Costa-Almeida R, Calejo I, Gomes ME. Mesenchymal stem cells empowering tendon regenerative therapies. *Int J Mol Sci* 2019;**20**(12):3002.
4. Liu C, Yu K, Bai J, Tian D, Liu G. Experimental study of tendon sheath repair via decellularized amnion to prevent tendon adhesion. *PLoS One* 2018;**13**(10):e0205811.
5. Griffin M, Hindocha S, Jordan D, Saleh M, Khan W. Suppl 1: Management of Extensor Tendon Injuries. *The Open Orthopaedics Journal* 2012;**6**:36.
6. Chang J, Neligan PC. Plastic Surgery E-Book: Volume 6: Hand and Upper Limb: Elsevier Health Sciences; 2017.
7. Lee YJ, Ryoo HJ, Shim H-S. Prevention of postoperative adhesions after flexor tendon repair with acellular dermal matrix in Zones III, IV, and V of the hand: A randomized controlled (CONSORT-compliant) trial. *Medicine* 2022;**101**(3).
8. Brebels J, Mignon A. Polymer-based constructs for flexor tendon repair: a review. *Polymers* 2022;**14**(5):867.
9. Moosavizadeh SM, Yavari M, Hassanpour SE, Soleimanzadeh P, Alavi M, Mahmoudvand H. The Use of Tamoxifen in Prevention of Adhesions after Flexor Tendons Surgery in Rabbits. *J Res Med Dental Sci* 2019;**7**(1):127-30.
10. Hassanpour S, Yavari M, Karbalaieikhani A. Comparison of two methods of flexor tendon retrieval in zone ii: hemi kessler core suture tendon retrieval and the use of long loop of nylon suture without pulling out the tendons from the sheath. 2011.
11. Shahraki SS, Yavari M, Tabrizi A. Effect of Amniotic Membrane Nerve Wrapping in Final Results of Traumatic Peripheral Nerve Repair. *World J Plastic Surg* 2022:0-.
12. Hortensius RA, Ebens JH, Dewey MJ, Harley BA. Incorporation of the amniotic membrane as an immunomodulatory design element in collagen scaffolds for tendon repair. *ACS biomaterials science & engineering* 2018;**4**(12):4367-77.
13. Wassmer C-H, Berishvili E. Immunomodulatory properties of amniotic membrane derivatives and their potential in regenerative medicine. *Curr Diab Rep* 2020;**20**:1-10.
14. Dogramaci Y, Duman IG. Reinforcement of the flexor tendon repair using human amniotic membrane: a biomechanical evaluation using the modified kessler method of tendon repair. *J Am Podiatr Med Assoc* 2016;**106**(5):319-22.
15. Leppänen OV, Karjalainen T, Göransson H, et al. Outcomes after flexor tendon repair combined with the application of human amniotic membrane allograft. *J Hand Surg* 2017;**42**(6):474. e1-. e8.
16. Sadraie SH, Parivar K, Arabi F, Moattari M, Kaka G, Mansouri K. Study of transected sciatic nerve repair by amniotic membrane with betamethasone in adult albino wistar rats. *Arch Iran Med* 2016;**19**(9):0-.
17. Fitriani N, Wilar G, Narsa AC, Mohammed AF, Wathoni N. Application of Amniotic Membrane in Skin Regeneration. *Pharmaceutics* 2023;**15**(3):748.
18. Walsh S, Midha R. Practical considerations concerning the use of stem cells for peripheral nerve repair. *Neurosurg Focus* 2009;**26**(2):E2.
19. Ramuta TŽ, Starčič Erjavec M, Kreft ME. Amniotic membrane preparation crucially affects its broad-spectrum activity against uropathogenic bacteria. *Front Microbiol* 2020;**11**:469.
20. Demirkan F, Colakoglu N, Herek O, Erkula G. The use of amniotic membrane in flexor tendon repair: an experimental model. *Arch Orthop Trauma Surg* 2002;**122**:396-9.