Original Article

Assessment of Concha Bullosa and Nasal Septal Deviation and Their Correlation with Palatal Dimensions in an Iranian Population Using Cone-Beam Computed Tomography

Foozie Zahedi[1], Abbas Shokri[2], Tayebe Ebrahimi[1*], Leili Tapak[3]

1. Department of Oral and Maxillofacial Radiology, Hamadan University of Medical Sciences, Hamadan, Iran
2. Dental Implant Research Center, Department of Oral and Maxillofacial Radiology, Hamadan University of Medical Sciences, Hamadan, Iran
3. Department of Biostatistics, School of Public Health and Research Center for Health Sciences, Hamadan University of Medical Sciences, Hamadan, Iran

***Corresponding Author:**

Dr. Tayebe Ebrahimi

Oral and Maxillofacial Radiology Department, Dental School, Hamadan University of Medical Sciences, Shahid Fahmideh Street, Hamadan, Iran.

Email: tydentist@gmail.com

Received: 7/7/2024
Accepted: 11/15/2025

ABSTRACT

Background: Obstruction of the upper airways may lead to dental and skeletal changes. Nasal septal deviation (NSD) and concha bullosa (CB) are associated with nasal airway obstruction. Mouth breathing is also linked to alterations in maxillary growth and palatal dimensions. This study aimed to compare palatal dimensions in Iranian individuals with and without NSD and CB using cone-beam computed tomography (CBCT).

Methods: This retrospective study analyzed 204 CBCT scans obtained with a large field of view. Scans were categorized into four groups based on the presence or absence of CB and NSD. The deviated septal curve angle (DSCA), palatal inter-alveolar length (PIL), palatal arch depth (PAD), and maxillopalatal arch angle (MPAA) were measured. Group comparisons were performed using one-way ANOVA, followed by post hoc pairwise tests.

Results: presence of CB was significantly associated with changes in mean PIL in both males and females (P=0.02). Only mean PIL showed significant sex differences, being longer in males than females (P=0.01). No significant differences in palatal dimensions were observed between individuals with and without NSD. The four groups differed significantly in mean PIL, MPAA, and DSCA (P<0.05).

Conclusion: CB may significantly alter palatal dimensions and could be associated with skeletal malocclusion. No significant differences in palatal depth and length were found between individuals with and without NSD.

KEYWORDS
Nasal Turbinates; Nasal Septum; Palate; Cone-Beam Computed Tomography (CBCT)

Please cite this paper as:
Zahedi F, Shokri A, Ebrahimi T, Tapak L. Assessment of Concha Bullosa and Nasal Septal Deviation and Their Correlation with Palatal Dimensions in an Iranian Population Using Cone-Beam Computed Tomography. World J Plast Surg. 2025;14(2):53-62.
doi: 10.61882/wjps.14.3.53

INTRODUCTION

Palatal height changes with growth and development; it increases continuously, with a higher rate between 5 to 16 years of age[1]. Sex may play an important role in determination of palatal dimensions and their changes during growth and development. The magnitude of increase in palatal dimensions has been reported to be greater in males than females [2, 3].

[Downloaded from wjps.ir on 2026-11-25]

[DOI: 10.61882/wjps.14.3.53]

Mouth breathing deprives individuals of the physiological benefits of nasal respiration and, if persistent, may lead to serious complications, particularly impaired growth and development of the facial skeleton. Mouth breathing can affect dental occlusion and leveling and alignment of the teeth. It also causes oral dryness, compromised gingival health, and can lead to incisal caries and oral malodor[4]. Adenoids hypertrophy have a major role in development of mouth breathing. Concha bullosa (CB), nasal septal deviation (NSD), and inferior turbinate hypertrophy as the parameters causing mechanical nasal obstruction may be involved in mouth breathing as well [5].

Normal nasal physiology may be altered by the presence of NSD and/or CB. Either condition may displace the middle turbinate laterally, narrow the middle meatus, induce nasal obstruction and exert pressure on adjacent anatomical structures. These changes in normal structures disturb the drainage pathways and impair mucociliary function. As a result, nasal blockage is exacerbated and the risk of infection increases [6].

The causes of NSD include trauma, developmental defects, congenital deformities, growth anomalies of the facial structures [7], finger sucking, tongue thrusting against the palate, and chronic mouth breathing. Trauma can damage the vomer and maxillary crest, particularly if it occurs before the complete ossification of these structures [7, 8].

Some studies have reported on the correlation between NSD and CB. CB can be unilateral or bilateral and is often associated with NSD towards the contralateral side [9]. The deviated septal curve angle (DSCA) plays an important role in concha pneumatization on the contralateral side[10]. NSD is more commonly associated with CB of the contralateral side. The higher incidence of unilateral CB, particularly the contralateral type, suggests that NSD may inhibit the development of ipsilateral CB [11]. A strong correlation has been reported between airway resistance and a high-arched palate [12]. Significant differences have been observed in the skeletal morphology of the maxilla between patients with airway problems and healthy controls, suggesting a potential etiologic role of airway issues in maxillary and palatal morphology. In the transverse plane, patients with airway problems often present with a narrow palatal arch, a V-shaped maxillary arch, and high-arched palate [13]. Assessment of palatal dimensions and nasal structures is clinically important, as therapeutic interventions such as rapid palatal expansion can significantly impact nasal anatomy [14].

Cone-beam computed tomography (CBCT) is widely used for precise measurement of airway volume and minimum cross-sectional area in routine clinical practice. It plays a crucial role in the assessment and management of various airway disorders. CBCT has been shown to be as accurate as other gold-standard methods for measuring upper airway volume and constricted area [15].

Considering the scarcity of studies investigating the correlation between NSD, CB, and palatal dimensions on CBCT scans, the present study aimed to evaluate the relationship between NSD and CB with palatal dimensions in Iranian individuals, taking into account their age and gender. We hypothesized that there is a significant relationship between the presence of CB and NSD and the dimensions of the palate.

MATERIALS AND METHODS

The protocol of this retrospective study was approved by the Ethics Committee of Hamadan University of Medical Sciences (Ethical code: 140202191110). All patients consented to the use of their CBCT scans for research purposes, and none of the patients underwent radiation for the purpose of this study.

A total of 204 CBCT scans of male and female patients aged 17 to 60 years presenting to the Department of Oral and Maxillofacial Radiology at the School of Dentistry, Hamadan University of Medical Sciences (western Iran) for various therapeutic purposes (not related to this study) from 2021-2022 were retrieved from the archives and evaluated. The CBCT scans had been taken with CS9300 CBCT scanner (Carestream Dental, Rochester, NY, USA) with 16 x 17 cm^2 field of view, 90 kVp tube voltage, 5 mA tube current, and 300 µm voxel size. The slice thickness and interval were both 2 mm. From the volumetric images, selected slices were selected for analysis. All images were independently evaluated by two observers including an oral and maxillofacial radiologist and a postgraduate student of oral radiology with sufficient experience and training. In case of any disagreement between the two observers, another oral radiologist was consulted. The CBCT scans were evaluated again after a 2-week interval

[Downloaded from wjps.ir on 2026-11-25]

[DOI: 10.61882/wjps.14.3.53]

to assess the inter-observer and intra-observer agreements.

Inclusion criteria consisted of patients older than 16 years with permanent dentition. exclusion criteria were age under 16 years, edentulous patients, history of orthodontic treatment, poor quality CBCT scans, unknown field of view, incomplete visualization of the nasal cavity, presence of image artifacts (such as partial images and streak artifacts), and CBCT scans of patients with a history of maxillofacial trauma, sinonasal tumors, or cleft palate. Of all, two CBCT scans with partial visualization and eight scans with streak artifacts were excluded. Additionally, CBCT scans from patients with a history of maxillofacial trauma (n=3), sinonasal tumors (n=5), and cleft palate (n=4) were excluded.

The included CBCT scans were categorized into four groups based on the presence/absence of CB and NSD:

Group 1: CBCT scans of patients without NSD and CB (n=125)

Group 2: CBCT scans of patients with CB alone (n=44)

Group 3: CBCT scans of patients with NSD alone (n=23)

Group 4: CBCT scans of patients with both NSD and CB (n=12)

The sample size was calculated to be 204 according to similar previous studies [16,17], assuming a standard deviation of 12 for the palatal arch depth (PAD), a 95% confidence level ($\alpha = 0.05$), a study power of 90%, and an estimated 10% dropout rate.

The DSCA was measured on coronal CBCT sections according to the criteria described by Kajan et al[16], and Orhan et al[18]. The measurements were performed by identifying key anatomical landmarks including the crista galli, palate, and nasal septum, which were clearly visible in the selected sections. The anatomical landmarks used for the measurement of DSCA are shown in Figure 1. The P point refers to the location where the nasal septum attaches to the nasal floor.

- DSCA: The highest point of the deviated septum was considered as the vertex of an obtuse angle, drawn superiorly to the crista galli and inferiorly to point "P." In this study, a DSCA of less than 150 degrees was considered indicative of septal deviation.

PIL, PAD, and MPAA were measured according to the criteria described by Kajan et al [16].

- PIL: The distance between the midpoints of the cervical portion of the existing molar teeth on both sides.
- PAD: the perpendicular distance from point "P" to the interalveolar line.
- MPAA: the angle formed between two lines

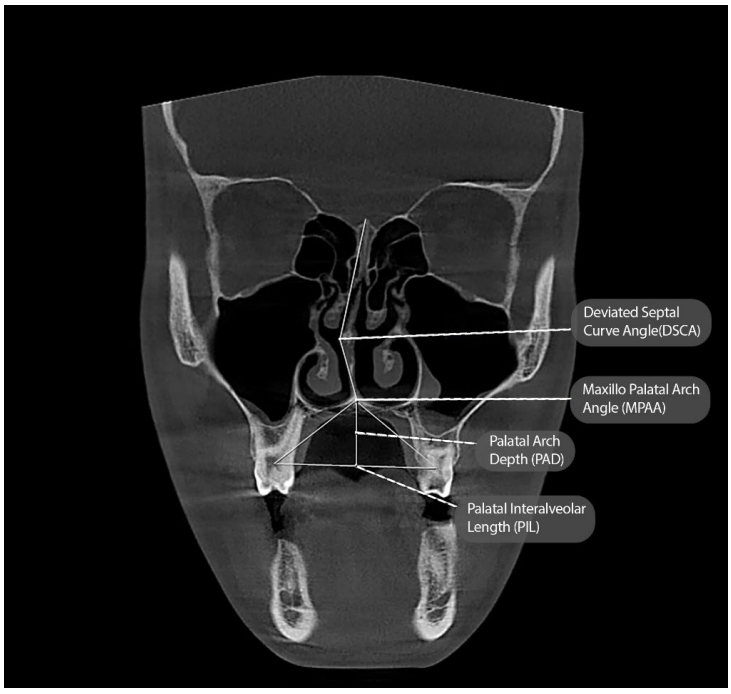

Figure 1: Coronal CBCT section illustrating the anatomical landmarks used to measure the degree of NSD, PIL, PAD and MPAA

[Downloaded from wjps.ir on 2026-11-25]

[DOI: 10.61882/wjps.14.3.53]

extending from point "P" to the midpoint of the alveolar ridge or dental arch on each side.

Figure 1 shows the radiographic landmarks used to measure the PIL, PAD, and MPAA.

The presence of CB was determined according to the criteria described by Stallman et al [19]. CB was considered present only when more than 50% pneumatization of the vertical height of the middle concha was observed on CBCT images (Figure 2).

The CBCT scans of patients with NSD were classified into groups 3 and 4. Data obtained from the CBCT images were analyzed using IBM SPSS Statistics, version 27 (IBM Co., Armonk, NY, USA). A general comparison among the groups was performed by ANOVA while pairwise comparisons were carried out by a post-hoc test.

All patients signed an informed consent form for the anonymous use of their data for research purposes.

RESULTS

All parameters evaluated in this study were measured twice by two observers, with a 2-week interval between measurements. The intraclass correlation coefficients for the MPAA, PAD, PIL, and DSCA were all greater than 0.8, indicating optimal intra-observer agreement. The kappa coefficient for the qualitative variables (NSD and CB) also indicated perfect intra-observer agreement. Inter-observer agreement was similarly high (ICC > 0.80) for all variables, which is considered acceptable according to the Cohen's classification (values ≤ 0 indicate no agreement, 0.01–0.20: slight, 0.21–0.40: fair, 0.41–0.60: moderate, 0.61–0.80: substantial, and 0.81–1.00: almost perfect agreement) [20].

Table 1 presents the frequency distribution of the evaluated variables. The mean age of the patients was 27±9.35 years, with no statistically significant difference between males and females.

The mean values of DSCA, PIL, PAD, and MPAA are presented in Table 1. Among these parameters, only the mean PIL showed a statistically significant difference between males and females (P=0.01), with males exhibiting higher values than females. No significant sex-based differences were observed in the mean DSCA, PAD, or MPAA (Table 2).

Additionally, in individuals with CB, the mean PIL was significantly higher in males than in females (P=0.02), with a difference of approximately 2 units (Table 2).

The mean values of DSCA, PAD, and MPAA were compared between males and females with NSD, and no statistically significant difference were observed in any of the parameters (Table 2).

Comparison of DSCA, PIL, PAD, and MPAA among the four groups revealed statistically significant differences in PIL, MPAA, and DSCA (P<0.05, Table 3). Pairwise comparisons using Tukey's test (Table 4) showed that the mean PIL and MPAA were significantly lower in the CB group compared

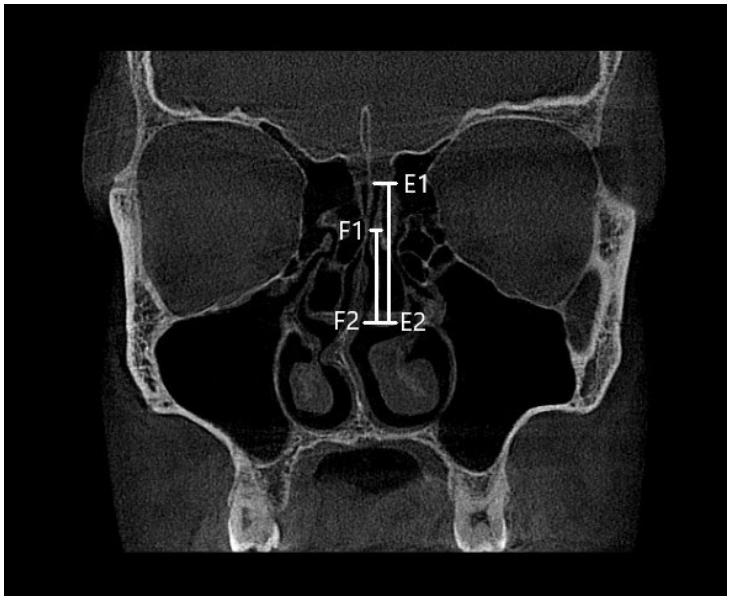

Figure 2: Coronal CBCT section showing identification of CB based on the criteria proposed by Stallman et al.[19] The E1–E2 line represents the vertical height of the middle turbinate, while the F1–F2 line indicates the extent of pneumatization due to CB

[Downloaded from wjps.ir on 2026-11-25]

[DOI: 10.61882/wjps.14.3.53]

Table 1: Characteristics of participants

A) Qualitative variables			
Variable	**Variable**	**Count**	**Percentage**
Gender	Female	104	51
	Male	100	49
CB	Present	56	27.5
	Absent	148	72.5
NSD	Present	35	17.2
	Absent	169	82.8

B) Quantitative variables					
Variable	**Number**	**Minimum**	**Maximum**	**Mean**	**Std. deviation**
DSCA	204	107.3	179.8	161.09	12.44
PIL	204	24.95	54.7	36.77	4.76
PAD	204	8.19	23.4	15.67	2.71
MPAA	204	66.1	136.1	97.32	12.88

CB: Concha bullosa. NSD: Nasal septal deviation. DSCA: Deviated septal curve angle. PIL: Palatal inter-alveolar length. PAD: Palatal arch depth. MPAA: Maxillopalatal arch angle

Table 2: Comparison of the mean quantitative variables between males and females

		All participants			**Participants with CB**			**Participants with NSD**		
Variable	**Gender**	**Mean**	**Std. deviation**	***P* value***	**Mean**	**Std. deviation**	***P* value***	**Mean**	**Std. deviation**	***P* value***
DSCA	Male	161.7	13.03	0.48	162.49	11.47	0.24	165.2	8.86	0.14
	Female	160.51	11.88		157.4	14.17		141.24	6.83	
PIL	Male	37.46	5.26	0.01	37.32	4.9	0.02	36.87	4.79	0.43
	Female	36.11	4.14		35.33	4.08		36.33	4.67	
PAD	Male	16.22	2.85	0.10	15.37	2.73	0.28	15.67	2.74	0.92
	Female	15.13	2.47		16.44	2.55		15.62	2.64	
MPAA	Male	96.6	13.06	0.43	91.26	11.60	0.37	97.28	13.88	0.97
	Female	98.01	12.74		93.94	10.53		97.14	13.10	

*Independent samples t-test. DSCA: Deviated septal curve angle. PIL: Palatal inter-alveolar length. PAD: Palatal arch depth. MPAA: Maxillopalatal arch angle. CB: Concha bullosa. NSD: Nasal septal deviation

Table 3: Comparison of the mean PIL, PAD, and MPAA among the four groups

Variable	**Group**	**Mean**	**Std. deviation**	***P* value***
PIL	Healthy	37.49	4.97	0.035
	CB	36.42	4.49	
	NSD	35.1	3.76	
	CB + NSD	36.17	5.21	
PAD	Healthy	15.38	2.73	0.09
	CB	15.35	2.74	
	NSD	16.51	2.6	
	CB + NSD	16.15	2.47	
MPAA	Healthy	99.38	13.16	0.006
	CB	91.55	12.84	
	NSD	97.82	9.95	
	CB + NSD	96.02	14.54	
DSCA	Healthy	166.26	7.56	0.001
	CB	162.2	11.38	
	NSD	141.97	6.00	
	CB+NSD	139.84	8.29	

*ANOVA. DSCA: Deviated septal curve angle. PIL: Palatal inter-alveolar length. PAD: Palatal arch depth. MPAA: Maxillopalatal arch angle. CB: Concha bullosa. NSD: Nasal septal deviation

[Downloaded from wjps.ir on 2026-11-25]

[DOI: 10.61882/wjps.14.3.53]

Table 4: Pairwise comparisons of the groups regarding PIL, PAD and MPAA by the Tukey's post-hoc test

Variable	Group (I)	Group (J)	Mean difference	*P* value
PIL	Healthy	NSD	1.06	0.31
		CB	2.38	0.004
		CB + NSD	1.32	0.35
	NSD	CB	1.31	0.27
		CB + NSD	0.25	0.88
	CB + NSD	CB	1.06	0.48
MPAA	Healthy	NSD	1.56	0.58
		CB	7.8	0.001
		CB + NSD	3.36	0.37
	NSD	CB	6.27	0.05
		CB + NSD	1.8	0.68
	CB + NSD	CB	4.47	0.27
NSD	Healthy	NSD	24.29	<0.001
		CB	4.06	0.033
		CB + NSD	26.42	<0.001
	NSD	CB	20.22	<0.001
		CB + NSD	2.13	0.89
	CB + NSD	CB	22.35	<0.001

PIL: Palatal inter-alveolar length. MPAA: Maxillopalatal arch angle. NSD: Nasal septal deviation. CB: Concha bullosa.

to the healthy group (P<0.05). Specifically, the mean MPAA in the healthy group was approximately 8 units greater than that in the CB group. Moreover, DSCA significantly differed between the healthy group and all other groups (P<0.05), between the NSD and CB groups, and between the CB + NSD group and the CB group.

DISCUSSION

In the current study, coronal CBCT scans of 104 females and 100 males were evaluated. There was no significant difference in the mean age between males and females across the four groups. The mean values of PIL, PAD, and MPAA were compared between males and females. The results revealed that only the PIL showed a significant difference, being higher in males than in females. This finding was in agreement with the results of Al-Zubair et al. [21] and Naser Eslami et al. [22], who also observed a greater PIL in males. This difference may be attributed to the smaller alveolar ridge size and weaker masticatory muscles in females. However, the current finding contradicts the results of Akbay et al. [23], who found no significant effect of gender on palatal dimensions. Ghasempour et al. [24] reported a significant gender-based difference in PAD but not in PIL. Such discrepancies in findings may be due to variations in sample size, methodology, or participant age, as Ghasempour et al. [24] evaluated individuals under 18 years of age, whose skeletal growth and jaw development may not have been complete.

There are two common sinonasal anatomical variants: middle turbinate CB and NSD. The incidence of NSD is lower in neonates compared to adults, and CB is generally absent in neonates. The prevalence of NSD increases with age, while CB typically becomes evident after the age of 7 years and may continue to develop beyond adolescence [8].

In cases of septal deviation, the increased space on the concave side of the nasal cavity may contribute to the development of CB and promote pneumatization of the middle turbinate. CB is commonly bilateral but tends to be less pneumatized on the side of the septal deviation [10].

There appears to be a possible developmental relationship between CB and NSD. One hypothesis suggests that NSD results in a widened nasal space on the concave side (ex vacuo), which allows the middle turbinate to expand and become pneumatized, leading to the formation of CB. In contrast, an alternative theory proposes that there is no causal association between unilateral CB and NSD, and that their coexistence is merely coincidental. According to this theory, CB does not necessarily develop as a compensatory response to NSD. Furthermore, pneumatization of the middle turbinate tends to

[Downloaded from wjps.ir on 2026-11-25]

[DOI: 10.61882/wjps.14.3.53]

be more prominent on the concave side of the nasal cavity, supporting the compensatory theory. However, this latter view is not fully supported by experimental and clinical evidence. Several studies have reported a statistically significant association between NSD and unilateral CB, although this relationship has not been consistently observed with bilateral CB [6, 10, 19, 25].

Uygur et al. [10] did not find any significant difference in the angle of septal deviation between patients with and without CB. They concluded that while septal deviation does directly cause the formation of CB it may enhance pneumatization of the middle turbinate depending on the degree of deviation.

In contrast, Aktas et al. [6] reported a significant relationship between NSD and unilateral CB; however, no such relationship was observed for bilateral CB in their study. These findings suggest a possible, yet not fully understood, developmental relationship between a concha and the nasal septum. Stallman et al.[19] highlighted this uncertainty by comparing it to the "chicken-and-egg" paradox. They found no definitive evidence to indicate whether the concha develops first, prompting the nasal septum to deviate away from it, or whether the septum deviates first, creating space that subsequently leads to conchal enlargement. Regardless of the sequence, septal deviation is often pronounced enough to cause narrowing of the contralateral nasal air channel. Notably, a strong association has been observed between the presence of a unilateral or dominant CB and contralateral NSD, particularly when the air passage between the concha and the septum remains preserved [19].

CB, or pneumatized middle turbinate, is considered the most common anatomical variant of the middle concha, with a reported prevalence ranging from 14% to 53.6%, as detected by computed tomography [19]. Although CB is often asymptomatic, excessively pneumatized turbinates can compromise the nasal airway, interfere with drainage of the osteomeatal complex, and predispose individuals to sinusitis [26]. Furthermore, Evidence suggests that inadequate nasal airflow during growth and development may result in chronic mouth breathing, which can contribute to varying degrees of maxillary constriction [27].

This study also compared the mean values of PIL, PAD, and MPAA between males and females with CB. Among these parameters, only the mean PIL showed a statistically significant difference, being higher in males. Similarly, Shetty et al. [17] reported that CB had a significant effect on PIL, supporting the findings of this study.

The mean values of PIL, PAD, and MPAA were also compared between males and females with NSD, and no statistically significant differences were found in any of these parameters. Similarly, Dalili Kajan et al. [16] reported no significant correlation between NSD and PAD. In contrast, Akbay et al. [23] found a significant positive correlation between NSD and PAD. The discrepancy between their findings and those of the present study may be attributed to differences in sample size and patient grouping strategies. Likewise, Shetty et al. [17] reported a positive statistical correlation between NSD and PAD, which also contradicts the current findings. Although the total sample size in their study was comparable to that of the present study, the NSD subgroup in their analysis was more than twice as large as that in the present research, which may explain the divergence in results. Additionally, differences in measurement techniques could have influenced the findings. For example, in both the current study and the study by Kajan et al.[16], the DSCA was measured using the angle formed by the highest point of the deviated septum (used as the vertex), the crista galli (superior reference), and point P (inferior reference). This specific measurement approach may have played a key role in the observed outcomes.

No significant correlation was observed between the mean DSCA and gender in this study. However, significant differences were found among the four study groups in terms of mean PIL, MPAA, and DSCA. Specifically, the mean DSCA in the CB + NSD group was smaller than that in both the healthy and NSD-only group. This finding suggests that the presence of CB is associated with a greater degree of NSD. Similar results were reported by Shetty et al. [17]. Although a definitive causal relationship between CB and NSD has not been established [25], several theories have been proposed. One theory suggests that NSD, depending on the degree of septal deviation (DSCA), may promote further pneumatization of an existing CB [10]. Conversely, another theory states that NSD may occur as a consequence of the presence of CB [6].

In the current study, the mean values of PIL and MPAA were significantly higher in the healthy group compared to the other three groups. Additionally, the mean PAD in the healthy group was significantly

[Downloaded from wjps.ir on 2026-11-25]

[DOI: 10.61882/wjps.14.3.53]

lower than that in the NSD and NSD + CB groups. These findings are consistent with previous studies by Kajan et al. [16], Shetty et al. [17], and Akbay et al.[23]. Akbay et al.[23] used computed tomography to evaluate the correlation of NSD and palatal dimensions, while Kajan et al. [16] investigated this relationship in the presence of CB. Although some previous studies reported a reduction in PIL and MPAA in patients with NSD and CB, these differences were not statistically significant. In contrast, in the current study, which included a larger sample size, this difference was statistically significant. This suggests that CB and NSD may have a measurable impact on palatal morphology. Changes in palatal dimensions associated with CB may be attributed to chronic nasal obstruction [28]. In cases of bilateral CB, asymmetry is common, with one side typically more pneumatized than the other; NSD often occurs on the side opposite to the dominant CB [29].

Nasal airway obstruction is commonly associated with a decrease in PIL and an increase in PAD [30]. In the present study, the presence of CB had a significant effect on PIL. Similarly, nasal obstruction and NSD were also correlated with a reduction in PIL [31]. However, studies specifically investigating the relationship between CB and PIL remain scarce. It has been suggested that continuous nasal airflow serves as a consistent stimulus for horizontal growth of the maxilla and the downward development of the palatal arch, which consequently leads to an increase in PIL [28].

The present findings highlight the potential clinical impact of nasal airway obstruction caused by CB on the inferior growth and development of the palatal arch. Early identification and management of CB may therefore be crucial in preventing maxillary deformation and the progression of malocclusion. These results may also provide valuable insight into nasal and craniofacial adaptations that occur during and following rapid palatal expansion, particularly in adolescent patients. Recent studies have demonstrated that rapid palatal expansion can induce skeletal changes not only in the nasal cavity but also in the craniofacial region and even the mandible [32, 33].

the correlation between CB and NSD with age, particularly in pediatric patients, was beyond the scope of this study. It is known that the size of the palate increases at the inter-canine and inter-molar regions as individuals transition from the primary to early permanent dentition. The current study was conducted on CBCT scans of adults with a large field of view, which were originally obtained for purposes unrelated to this research. All patients provided consent for to the use of their CBCT scans in the study, and no additional radiation was administered for research purposes. Due to the limited availability of pediatric CBCT scans with a large field of view, , we were unable to include pediatric patients in this study. One of the main limitations of this study was the evaluation of parameters in two-dimensional views. Future studies are recommended to use larger sample size and incorporate different radiographic modalities and multi-dimensional analyses to obtain more comprehensive data.

CONCLUSION

The findings of this study indicate that CB can significantly influence palatal dimensions, with the palatal interalveolar length (PIL) showing the strongest correlation with its presence. When CB coexisted with NSD, significant associations were also observed between PIL, MPAA, and DSCA. In contrast, NSD alone did not demonstrate a significant effect on palatal depth or length. These results suggest that, unlike NSD, CB may play a more prominent role in altering palatal dimensions and contributing to skeletal malocclusion.

ACKNOWLEDGMENTS

No financial source was received for this study.

CONFLICT OF INTEREST

The authors declare that there is no conflict of interests.

REFERENCES

1. Thilander B. Dentoalveolar development in subjects with normal occlusion. A longitudinal study between the ages of 5 and 31 years. *Eur J Orthod* 2009;**31**(2):109-20.
2. Hassanali J, Odhiambo JW. Analysis of dental casts of 6-8-and 12-year-old Kenyan children. *Eur J Orthod* 2000;**22**(2):135-42.
3. Eslami Amirabadi G, Golshah A, Derakhshan S, Khandan S, Saeidipour M, Nikkerdar N. Palatal dimensions at different stages of dentition in 5 to

[Downloaded from wjps.ir on 2026-11-25]

[DOI: 10.61882/wjps.14.3.53]

18-year-old Iranian children and adolescent with normal occlusion. *BMC Oral Health* 2018;**18**:1-6.
4. Kanehira T, Takehara J, Takahashi D, Honda O, Morita M. Prevalence of oral malodor and the relationship with habitual mouth breathing in children. *J Clin Pediatr Dent* 2004;**28**(4):285-8.
5. Farid M, Metwalli N. Computed tomographic evaluation of mouth breathers among paediatric patients. *Dentomaxillofac Radiol* 2010;**39**(1):1-10.
6. Aktas D, Kalcioglu MT, Kutlu R, Ozturan O, Oncel S. The relationship between the concha bullosa, nasal septal deviation and sinusitis. *Rhinology* 2003;**41**(2):103-6.
7. Neskey D, Eloy JA, Casiano RR. Nasal, septal, and turbinate anatomy and embryology. *Otolaryngologic Clinics of North America* 2009;**42**(2):193-205.
8. Balikci HH, Gurdal MM, Celebi S, Ozbay I, Karakas M. Relationships among concha bullosa, nasal septal deviation, and sinusitis: Retrospective analysis of 296 cases. *Ear, Nose & Throat Journal* 2016;**95**(12):487-91.
9. Alper F, Karasen RM, Kantarci M. A massive superior concha bullosa: case report and literature review. *Rhinology* 2004;**42**(1):38-40.
10. Uygur K, TÜz M, Doğru H. The correlation between septal deviation and concha bullosa. *Otolaryngology—Head and Neck Surgery* 2003;**129**(1):33-6.
11. Yiğit Ö, Acıoğlu E, Çakır ZA, Şişman AS, Barut AY. Concha bullosa and septal deviation. *European archives of oto-rhino-laryngology* 2010;**267**:1397-401.
12. Johal A, Conaghan C. Maxillary morphology in obstructive sleep apnea: a cephalometric and model study. *The Angle Orthodontist* 2004;**74**(5):648-56.
13. Gungor AY, Turkkahraman H. Effects of airway problems on maxillary growth: a review. *European journal of dentistry* 2009;**3**(03):250-4.
14. Giudice AL, Spinuzza P, Rustico L, Messina G, Nucera R. Short-term treatment effects produced by rapid maxillary expansion evaluated with computed tomography: A systematic review with meta-analysis. *Korean Journal of Orthodontics* 2020;**50**(5):314-23.
15. Tsolakis IA, Venkat D, Hans MG, Alonso A, Palomo JM. When static meets dynamic: Comparing cone-beam computed tomography and acoustic reflection for upper airway analysis. *American Journal of Orthodontics and Dentofacial Orthopedics* 2016;**150**(4):643-50.
16. Kajan ZD, Khademi J, Nemati S, Niksolat E. The effects of septal deviation, concha bullosa, and their combination on the depth of posterior palatal arch in cone-beam computed tomography. *J Dent* 2016;**17**(1):26.
17. Shetty SR, Al Bayatti SW, Al-Rawi NH, et al. The effect of concha bullosa and nasal septal deviation on palatal dimensions: a cone beam computed tomography study. *BMC Oral Health* 2021;**21**:1-10.
18. Orhan I, Ayd1n S, Ormeci T, Y1ilmaz F. A radiological analysis of inferior turbinate in patients with deviated nasal septum by using computed tomography. *Am J Rhinol Allergy* 2014;**28**(1):e68-e72.
19. Stallman JS, Lobo JN, Som PM. The incidence of concha bullosa and its relationship to nasal septal deviation and paranasal sinus disease. *Am J Neuroradiol* 2004;**25**(9):1613-8.
20. Naidoo N, Maria S, Flanagan B, Van Noordenburg A, Ho V, Mansour V. A multiphase mixed-methods participatory approach to Paramedicine educators' identity, intersectionality, and impediments to professional emergence. 2024.
21. Al-Zubair NM. Determinant factors of Yemeni maxillary arch dimensions. *The Saudi Dental Journal* 2015;**27**(1):50-4.
22. Nasereslami F, Razi T, Banakar E, Emamverdizadeh P, Razi S. Comparison of Dimensions of the Palate Between Individuals With and Without Nasal Septum Deviation on Cone-Beam Computed Tomography Images in an Iranian Population. *Avicenna Journal of Dental Research* 2022;**14**(4):160-4.
23. Akbay E, Cokkeser Y, Yilmaz O, Cevik C. The relationship between posterior septum deviation and depth of maxillopalatal arch. *Auris Nasus Larynx* 2013;**40**(3):286-90.
24. Ghasempour M, Mohammadzadeh I, Garakani S. Palatal arch diameters of patients with allergic rhinitis. Iran J Allergy Asthma Immunol 2009;8(1):63-4.
25. Keles B, Öztürk K, Ünaldı D, Arbag H, Özer B. Is there any relationship between nasal septal deviation and concha bullosa? *Eur J General Med* 2010;**7**(4):359-64.
26. Erbek S. Dursun E. *Konka bülloza nedenli orta konka baş ağrısı sendromu Kulak Burun Boğaz ve Baş Boyun Cerrahisi Dergisi* 2002;**10**:150-5.
27. Cellina M, Gibelli D, Cappella A, Martinenghi C, Belloni E, Oliva G. Nasal cavities and the nasal septum: Anatomical variants and assessment of features with computed tomography. *Neuroradiol J* 2020;**33**(4):340-7.
28. Cukurova I, Yaz A, Gumussoy M, Yigitbasi OG, Karaman Y. A patient presenting with concha bullosa in another concha bullosa: a case report. *Journal of Medical Case Reports* 2012;**6**:1-4.
29. Karataş D, Yüksel F, Koç A. Volumetric correlation between concha bullosa and paranasal sinuses. *J Anat Soc India* 2017;**66**(2):131-4.
30. Berwig LC, Silva AMTd, Côrrea ECR, Moraes ABd, Montenegro MM, Ritzel RA. Hard palate dimensions in nasal and mouth breathers from different etiologies. *Jornal da Sociedade Brasileira de Fonoaudiologia* 2011;**23**:308-14.

[Downloaded from wjps.ir on 2026-11-25]

[DOI: 10.61882/wjps.14.3.53]

31. Indiarti IS, Setyanto D, Kusumaningrum A, Budiardjo SB. Changes in the palatal dimensions of mouth breathing children caused by nasal obstruction. *Journal of Physics: Conference Series* 2017: IOP Publishing; 2017. p. 012036.
32. Leonardi R, Ronsivalle V, Lagravere MO, Barbato E, Isola G, Lo Giudice A. Three-dimensional assessment of the spheno-occipital synchondrosis and clivus after tooth-borne and bone-borne rapid maxillary expansion: a retrospective CBCT study using voxel-based superimposition. *The Angle Orthodontist* 2021;**91**(6):822-9.
33. Lo Giudice A, Ronsivalle V, Lagravere M, Leonardi R, Martina S, Isola G. Transverse dentoalveolar response of mandibular arch after rapid maxillary expansion (RME) with tooth-borne and bone-borne appliances: A CBCT retrospective study. *The Angle Orthodontist* 2020;**90**(5):680-7.

[Downloaded from wjps.ir on 2026-11-25]

[DOI: 10.61882/wjps.14.3.53]