Original Article

Evaluation of Airway Changes Following Isolated Unilateral mandibular Fracture: A Prospective Quasi-Experimental

Moosa Mahmoudi [1], Sara Samiei [1], Sarina Hassanpour Dargah [1], Ali Labafchi [1,2*]

1. Department of Oral and Maxillofacial Surgery, Kerman University of Medical Sciences, Kerman, Iran
2. Student Research Committee, Dental School, Kerman University of Medical Sciences, Kerman, Iran

ABSTRACT

Background: Maxillofacial trauma presents unique airway management challenges due to anatomical disruptions, soft tissue compromise, edema, hemorrhage, and emesis. While isolated mandibular fractures are typically non-emergent, specific fracture patterns can precipitate airway obstruction secondary to bony fragment displacement. There is a paucity of data on airway changes after unilateral mandibular fractures. This prompted us to conduct the present study.

Methods: This prospective, quasi-experimental study enrolled patients with isolated unilateral mandibular fractures requiring surgical reduction between December 2023 and December 2024. Airway changes were assessed via lateral cephalometric analysis pre-operatively and at a 3-month post-operative interval. Specifically, the distances of the posterior nasal spine (PSP), the intersection of the inferior border of the mandible with the posterior tongue (PTO), and the highest point of the epiglottis (E) from the PRL reference line (a vertical line connecting the Porion (PO) to the Frankfort plane) were measured and compared on pre- and post-operative cephalometric radiographs. Descriptive and bivariate statistics were employed, with statistical significance defined as $P < 0.05$.

Results: Twenty eight patients, including 18 males and 10 females with a mean age of 34.4 ± 14.1 years, were investigated. Post-treatment, the average airway space increased slightly at all measured points: PSP (23.6 mm to 23.8 mm, P=0.222), PTO (22.0 mm to 22.1 mm, P=0.366), and E (12.6 mm to 12.9 mm, P=0.590).

Conclusion: Although slight increases in airway space were observed post-treatment at all measured points (PSP, PTO, and E), none of these changes were statistically significant.

KEYWORDS
Mandibular fracture; Airway changes; Trauma

Please cite this paper as:
Mahmoudi M, Samiei S, Hassanpour Dargah S, Labafchi A. Evaluation of Airway Changes Following Isolated Unilateral mandibular Fracture: A Prospective Quasi-Experimental. World J Plast Surg. 2025;14(3):79-85.
doi: 10.61882/wjps.14.3.79

***Corresponding Author:**

Ali Labafchi

Department of Oral and Maxillofacial Surgery, Kerman University of Medical Sciences, Kerman, Iran AND Student Research Committee, Dental School, Kerman University of Medical Sciences, Kerman, Iran

Email: labafchiali@yahoo.com

Received: 5/1/2025
Accepted: 11/10/2025

INTRODUCTION

The maxillofacial skeleton is recognised as a highly vulnerable area, making its fractures among the most common injuries encountered in trauma patients [1-3]. Bilateral mandibular fractures pose a significant risk of airway compromise, potentially leading to narrowing or complete obstruction. This is primarily due to posterior tongue displacement,

[Downloaded from wjps.ir on 2026-11-25]

[DOI: 10.61882/wjps.14.3.79]

soft tissue swelling, and edema. The fractured bone fragment becomes a free-moving segment, subject to displacement by the attached musculature, including the mylohyoid, digastric, geniohyoid, and genioglossus muscles. This displacement often necessitates urgent intervention. Furthermore, life-threatening complications, such as sublingual hematoma, extensive soft tissue edema, aspiration of foreign bodies (such as teeth or bone fragments), and blood accumulation within the oral cavity and oropharynx, can further exacerbate airway compromise in patients with bilateral mandibular fractures [4-7].

The distribution of mandible fractures, based on recent research, reveals that condylar and body fractures are the most prevalent (35.4% and 35%, respectively), with decreasing frequency observed in angle (28.9%), parasymphysis (25.3%), symphysis (11%), alveolar (10.8%), ramus (1.7%), and coronoid (0.4%) fractures [8].

The potential for life-threatening airway compromise following mandible fractures necessitates rapid diagnosis and appropriate intervention. Optimal management of these patients requires a collaborative effort among maxillofacial surgeons, anesthesiologists, and other relevant specialists to ensure patient safety and positive outcomes [6, 9, 10]. The existing literature on upper airway morphology and function predominantly addresses conditions such as obstructive sleep apnea syndrome, orthodontic and orthognathic surgical interventions, and congenital craniofacial anomalies, including cleft lip and palate. In contrast, the effects of isolated mandible fractures and their associated morphological changes on upper airway dimensions are sparsely documented. While these fractures are generally considered non-life-threatening and are managed in a non-emergent setting, the potential for airway obstruction secondary to bone fragment displacement in specific fracture patterns warrants further investigation [9].

Despite the emphasis placed on airway assessment and management in established trauma protocols, the literature provides limited data regarding airway changes specifically associated with unilateral mandible fractures. Therefore, we aimed to evaluate these changes and to determine the relationship between the pattern of mandibular fracture and the occurrence of airway narrowing or obstruction.

MATERIALS AND METHODS

Study design

A prospective, before-after interventional study was conducted at the Department of Maxillofacial Surgery, Bahonar Hospital, Kerman, Iran, from December 2023 to December 2024. The study protocol was approved by the Ethics and Research Committee of Kerman University of Medical Sciences (IR.KMU.REC.1402.350).

The inclusion criteria for this study were designed to select a homogenous population of patients with isolated, unilateral mandible fractures requiring surgical intervention. Participants were required to be between 18 and 60 years of age, classified as ASA Class I or II, and provide informed consent. Patients were excluded if they presented with confounding factors that could influence airway measurements, such as a history of substance abuse, maternal syndromes, severe maxillary deviations affecting respiratory function, pre-existing respiratory conditions (rhinitis, asthma, bronchitis), or a history of adenoidectomy or pharyngeal flap surgery. Patients who withdrew from the study were also excluded.

To ensure consistency and quality, all radiographs were performed using a standardised technique: 60-70 kVp, 5-second exposure time, and a consistent source-to-image receptor distance. A trained technician was responsible for ensuring that all procedures met the established standards. In addition, demographic information (age and gender), medical and dental histories, fracture type, and trauma etiology were recorded for each patient.

The protocol of anesthesia and surgical procedure

Surgical management, consisting of the reduction and fixation of isolated unilateral mandibular fractures, was performed on all patients by a single surgical team following a standardized general anesthesia protocol. Intraoperative physiological monitoring was conducted continuously using pulse oximetry, electrocardiography, thermal probes, and capnography. This monitoring strategy facilitated close observation of key hemodynamic parameters, including heart rate and mean arterial pressure, thereby promptly identifying and managing potential intraoperative complications such as bradycardia or significant hypotensive episodes.

[Downloaded from wjps.ir on 2026-11-25]

[DOI: 10.61882/wjps.14.3.79]

Variables and data collection

Comprehensive patient records were compiled, including demographic characteristics (age, gender), pertinent medical and dental histories, fracture classification, and mechanism of injury. Lateral cephalometric radiographs were acquired both preoperatively and at a 3-month postoperative interval, after the removal of all intraoral fixation devices. In instances where preoperative computed tomography (CT) imaging was available, reconstructed lateral cephalograms derived from sagittal reformations were utilized for analysis. Pharyngeal airway tracings were performed on each cephalometric radiograph according to a standardized protocol. This involved the identification of 14 anatomical landmarks and the subsequent plotting of 7 linear variables within the defined boundaries of the pharyngeal airway space (PAS). Key landmarks included Sella (S), Nasion (N), and the Frankfort horizontal and pterygomandibular vertical planes (PTV).

Airway changes were quantified by measuring the linear distances between specific anatomical landmarks and the PRL reference line on preoperative and 3-month postoperative lateral cephalograms (Figure 1). The measured landmarks were: PSP (posterior nasal spine), PTO (intersection of the mandibular lower border and posterior tongue), and E (highest point of the epiglottis). The PRL was defined as a vertical line extending from the Porion (PO) point to the Frankfort plane. These measurements were then compared to assess changes in airway dimensions.

Data analyses

Relative frequency and the mean central index were used to analyses the descriptive statistics of the data. The Chi-square and Wilcoxon signed-rank tests were employed to compare the deviation frequency between the two groups. The SPSS software version 21 (IBM Corp., Armonk, NY, USA) was utilized to generate the results. *P* value<.05 was considered statistically significant.

RESULTS

We evaluated 28 patients, including 18 men and 10 women, with a mean age of 41.14 ± 4.34 years, ranging from 18 to 60 years, based on age, gender, and post-treatment airway changes. The patients' mandible fractures were analyzed, with the most common being condylar fractures (right condyle, four patients,14.3%; left condyle,5 patients,17.9%; and in total condyle fracture,9 patients, 32.2%). Of these patients, 17 received open reduction treatment (60.7%), while 11 underwent closed reduction treatment (39.3%).

Table 1 shows that the mean pre-treatment pharyngeal airway space (PSP) was 6.23 mm, increasingto8.23mmpost-treatment(*P*value=0.222).

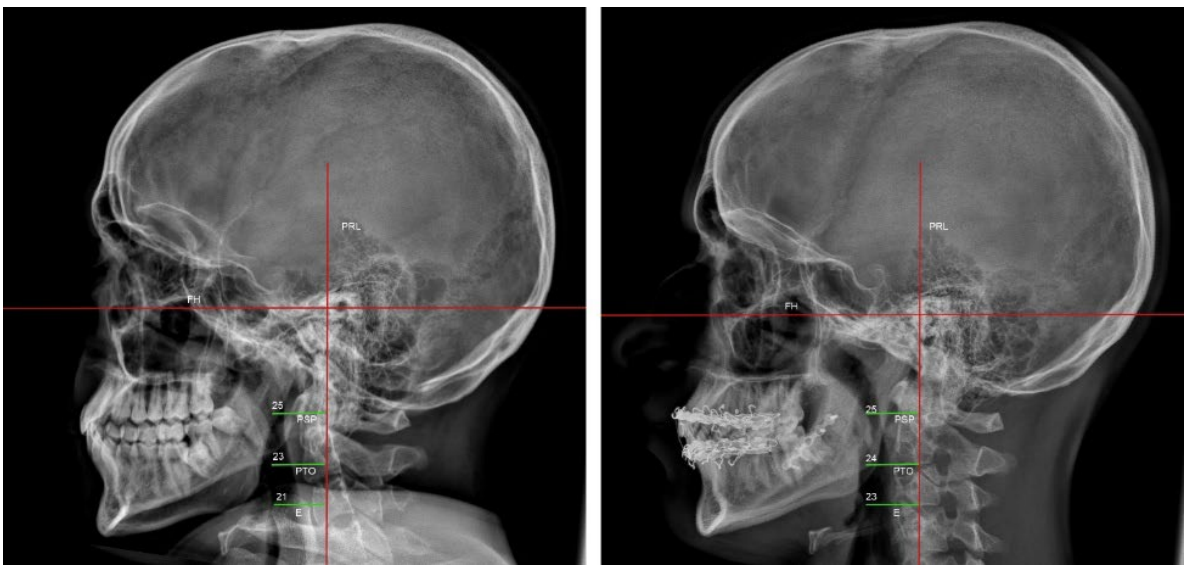

Figure 1: The sample case presented is a cephalometric analysis and pharyngeal airway tracing of a left-sided angle mandible fracture patient

[Downloaded from wjps.ir on 2026-11-25]

[DOI: 10.61882/wjps.14.3.79]

Table 1: Comparison of pharyngeal airway spaces before and after treatment

Variable	Number	Mean	Standard deviation	Max	Min	Will the Coxon Test Result
The distance from PSP to the reference line before treatment	28	23.6429	2.29677	28.00	20.00	0.222
The distance from PSP to the reference line after treatment	28	23.8214	2.21198	27.00	20.00	
The distance from PTO to the reference line before treatment	28	22.0000	2.26078	27.00	19.00	0.366
The distance from PTO to the reference line after treatment	28	22.1071	2.19999	27.00	19.00	
The distance from E to the reference line before treatment	28	12.6071	2.23340	25.00	18.00	0.590
The distance from E to the reference line after treatment	28	12.9286	1.98006	25.00	18.00	

Similarly, the mean pre-treatment PTO airway space was 22 mm, increasing to 22.1 mm post-treatment (*P* value=0.366). The mean pre-treatment E airway space was 6.12 mm, increasing to 9.12 mm post-treatment (*P* value=0.590). Although an increase in airway space was observed in each group, these changes were not statistically significant.

The statistical analysis revealed no significant association between gender and the type of fracture (*P*=0.09), indicating that gender does not influence the type of mandibular fracture in the studied population.

Table 2 shows however, when analyzing the relationship between the type of fracture and the treatment method, a significant difference was found among the groups (*P*<0.001). Specifically, condylar fractures were more likely to be treated with closed reduction, suggesting that this treatment method might be preferred for this type of fracture.

DISCUSSION

The primary focus of this study was to investigate changes in the airway following isolated and unilateral mandibular fractures, both before and after treatment. The results demonstrated an increase in airway space post-treatment; however, these changes were not found to be statistically significant.

The initial priority in any trauma protocol is the evaluation and management of the airway, particularly in cases involving facial trauma. According to a 10-year retrospective study at a Level 1 trauma center, approximately 17% of patients with facial fractures required airway intervention. However, the need for airway intervention following isolated and unilateral mandibular fractures, specifically in cases of blunt trauma, was significantly lower [11].

In the present study, the most common sites of mandibular fracture were the condylar region (9 patients, 32%), followed by the mandibular body (6 patients,22%). Alassaf et al. reported an equal prevalence of condylar and body fractures (27 cases, 38% each) [6]. The condylar fracture has been recognized as the most frequent site of mandibular fracture by Samman et al. [12]. Bormann et al. reported the condylar fracture as the most prevalent type (42%), followed by the parasymphysis (21%) [13]. Furthermore, the mandibular body fracture was the most common type reported by Rabi and Al-Khateeb [14]. The findings of the current study align with the studies mentioned above.

Mandibular fractures account for less than 10% of all facial fractures and are less common than nasal, orbital, or maxillary bone fractures. In a retrospective study by Tung et al., only 3 out of 1,025 patients (0.3%) with isolated mandibular fractures experienced airway compromise requiring urgent management. Notably, these 3 cases were likely attributed to large neck hematomas in 2 patients and a nasopharyngeal obstruction in the other [15].

[Downloaded from wjps.ir on 2026-11-25]

[DOI: 10.61882/wjps.14.3.79]

[DOI: 10.61882/wjps.14.3.79] [Downloaded from wjps.ir on 2026-11-25]

Table 2: Investigating the relationship between the type of fracture and the treatment method

Variable			Symphysis	Lt. Parasymphysis	Rt. parasymphysis	Lt. Angle	Rt.angle	Lt. Body	Rt. Body	Lt. Condyle	Rt.condyle	Total
TREATMENT	CR	Population	1	1	0	0	0	0	0	5	4	11
		Percentage	25.0%	100.0%	0.0%	0.0%	0.0%	0.0%	0.0%	100.0%	100.0%	39.3%
	ORIF	Number	3	0	4	2	2	2	4	0	0	17
		Percentage	75.0%	0.0%	100.0%	100.0%	100.0%	100.0%	100.0%	0.0%	0.0%	60.7%
Total		Number	4	1	4	2	2	2	4	5	4	28
		Percentage	100.0%	100.0%	100.0%	100.0%	100.0%	100.0%	100.0%	100.0%	100.0%	100%
Chi-square test result										0.001		

Assessing and managing the airway is the primary concern for trauma patients, particularly in cases of severe facial trauma. Significant swelling or displacement of facial bones, sublingual hematomas, diffuse oropharyngeal bleeding, unprovoked nasal bleeding, or external body aspiration should all be considered carefully. It appears that an isolated mandibular fracture, without significant displacement, rarely causes airway obstruction in the absence of other soft tissue injuries [16] [10].

Chen et al. reported that the hyoid bone position does not change significantly in unilateral mandibular fractures and has no direct connection with the airway. However, the hyoid bone position changes in bilateral and comminuted fractures, moving downward and backward. The genioglossus muscle, which attaches to the mandible, is pulled upward, and the tongue base moves backwards, resulting in a narrower airway. The findings of the present study are consistent with the study mentioned above [17].

Famurewa et al. investigated the respiratory function of patients with isolated mandibular fractures. They concluded that in cases of isolated, unilateral, nondisplaced mandibular fractures in conscious patients, a degree of respiratory dysfunction may be present, but it is tolerable by patients. According to the study, among all unilateral mandibular fractures, only the mandibular body fracture has a potential impact on the airway [11]. In contrast, the current study found no relationship between respiratory function patterns and fracture sites, likely due to the small sample size.

Alassaf et al. examined morphological changes in the airway following facial fractures. Their findings demonstrated a significant difference between unilateral and bilateral fractures, with more substantial airway alterations occurring in bilateral fractures [6].

Limited studies have investigated airway changes following mandibular fractures. In recent years, pharyngeal airway space (PAS) narrowing after mandibular setback surgery has garnered increased attention due to its potential role as a predisposing factor for obstructive sleep apnea (OSA) development [14, 17, 18]. However, dos Santos Canellas, Demetriades, and Erikson reported contradictory findings in their respective studies, suggesting that the impact of mandibular setback surgery on the development of OSA remains controversial [19-21].

CONCLUSION

The results demonstrated an increase in airway space post-treatment, although these changes were not statistically significant. This suggests that while treating mandibular fractures may lead to increased airway dimensions, the extent of change is not significant enough to affect respiratory function substantially.

ACKNOWLEDGMENTS

The authors appreciate the continued support of the Research Council of Kerman University of Medical Sciences and Student Research Committee, Kerman, Iran.

CONFLICT OF INTEREST

The authors declare that there is no conflict of interests.

REFERENCES

1. Goh EZ, Beech N, Johnson NR. Traumatic maxillofacial and brain injuries: a systematic review. *Int J Oral Maxillofac Surg* 2021 Aug;**50**(8):1027-33.
2. AlGhamdi S, Alasmari FS, Alarjani MB, et al. Association between maxillofacial fractures and brain injuries in trauma patients: a cross-sectional study in the Kingdom of Saudi Arabia. *Pan Afr Med J* 2022;**43**:193.
3. Tselnik M, Pogrel MA. Assessment of the pharyngeal airway space after mandibular setback surgery. *J Oral Maxillofac Surg* 2000 Mar;**58**(3):282-5; discussion 5-7.
4. Galvagno SM, Jr., Nahmias JT, Young DA. Advanced Trauma Life Support(®) Update 2019: Management and Applications for Adults and Special Populations. *Anesthesiol Clin* 2019 Mar;**37**(1):13-32.
5. Assiri ZA, Salma REG, Almajid EA, Alfadhel AK. Retrospective radiological evaluation to study the prevalence and pattern of maxillofacial fracture among Military personal at Prince Sultan Military Medical City [PSMMC], Riyadh: An institutional study. *Saudi Dent J* 2020 Jul;**32**(5):242-9.
6. Alassaf MS, Khan HK, Habib OA, Aboalkhair AE, Albeshir HA, Samman MM. Morpho-Volumetric Changes of the Pharyngeal Airway With Traumatic Maxillofacial Injuries: A Retrospective Radiographic

[Downloaded from wjps.ir on 2026-11-25]

[DOI: 10.61882/wjps.14.3.79]

Study. *Cureus* 2023 Oct;**15**(10):e47081.
7. Papadiochos I, Goutzanis L, Petsinis V. Flail Mandible and Immediate Airway Management: Traumatic Detachment of Mandibular Lingual Cortex Results in Obstructive Dyspnea and Severe Odynophagia. *J Craniofac Surg* 2017 Jul;**28**(5):1311-4.
8. Farzan R, Farzan A, Farzan A, Karimpour M, Tolouie M. A 6-Year Epidemiological Study of Mandibular Fractures in Traumatic Patients in North of Iran: Review of 463 Patients. *World J Plast Surg* 2021 Jan;**10**(1):71-7.
9. Barak M, Bahouth H, Leiser Y, Abu El-Naaj I. Airway Management of the Patient with Maxillofacial Trauma: Review of the Literature and Suggested Clinical Approach. *Biomed Res Int* 2015;**2015**:724032.
10. Le TT, Oleck NC, Khan W, et al. Implications of Facial Fracture in Airway Management of the Adult Population: What Is the Most Effective Management Strategy? *Ann Plast Surg* 2019 Apr;**82**(4S Suppl 3):S179-s84.
11. Famurewa BA, Oginni FO, Aregbesola SB, Erhabor GE. Pulmonary functions of patients with isolated mandibular fractures: a preliminary report. *J Korean Assoc Oral Maxillofac Surg* 2020 Feb;**46**(1):36-40.
12. Samman M, Ahmed SW, Beshir H, Almohammadi T, Patil SR. Incidence and Pattern of Mandible Fractures in the Madinah Region: A Retrospective Study. *J Nat Sci Biol Med* 2018 Jan-Jun;**9**(1):59-64.
13. Bormann KH, Wild S, Gellrich NC, et al. Five-year retrospective study of mandibular fractures in Freiburg, Germany: incidence, etiology, treatment, and complications. *J Oral Maxillofac Surg* 2009 Jun;**67**(6):1251-5.
14. Alqahtani F, Bishawi K, Jaber M. Analysis of the pattern of maxillofacial injuries in Saudi Arabia: A systematic review. *Saudi Dent J* 2020 Feb;**32**(2):61-7.
15. Tung TC, Tseng WS, Chen CT, Lai JP, Chen YR. Acute life-threatening injuries in facial fracture patients: a review of 1,025 patients. *J Trauma* 2000 Sep;**49**(3):420-4.
16. Pyfer BJ, Cason RW, Mundy L, Powers DB, Erdmann D. Acute Airway Compromise After Isolated Mandibular Subcondyle Fracture in a Patient With a Hemi-Mandible: A Case Report. *Craniomaxillofacial Trauma & Reconstruction Open* 2021 2021/01/01;**6**:24727512211035254.
17. Chen LJ, Zhao MC, Pan XF, Wei YQ, Wang DY. X-cephalometric study of different parts of the upper airway space and changes in hyoid position following mandibular fractures. *West Indian Med J* 2013 Sep;**62**(7):642-8.
18. Hochban W, Schürmann R, Brandenburg U, Conradt R. Mandibular setback for surgical correction of mandibular hyperplasia--does it provoke sleep-related breathing disorders? *Int J Oral Maxillofac Surg* 1996 Oct;**25**(5):333-8.
19. Schilbred Eriksen E, Gulati S, Moen K, Wisth PJ, Løes S. Apnea-Hypopnea Index in Healthy Class III Patients Treated With Intraoral Vertical Ramus Osteotomy: A Prospective Cohort Study. *J Oral Maxillofac Surg* 2019 Mar;**77**(3):582-90.
20. Demetriades N, Chang DJ, Laskarides C, Papageorge M. Effects of mandibular retropositioning, with or without maxillary advancement, on the oro-naso-pharyngeal airway and development of sleep-related breathing disorders. *J Oral Maxillofac Surg* 2010 Oct;**68**(10):2431-6.
21. Kitagawara K, Kobayashi T, Goto H, Yokobayashi T, Kitamura N, Saito C. Effects of mandibular setback surgery on oropharyngeal airway and arterial oxygen saturation. *Int J Oral Maxillofac Surg* 2008 Apr;**37**(4):328-33.

[Downloaded from wjps.ir on 2026-11-25]

[DOI: 10.61882/wjps.14.3.79]