

Factors Contributing to Dental Implants Displacement inside the Maxillary Sinus and Their Treatment: A Systematic Review

Nima Dehghani^{1*}, Mohadeseh Azarsina², Xaniar Mahmoudi³, Mona Mohajeri Tehrani⁴, Shamim Chinian⁵

1. Department of Oral and Maxillofacial Surgery, Tehran University of Medical Sciences, Tehran, Iran
2. Department of Esthetic and Restorative Dentistry, School of Dentistry, Tehran University of Medical Sciences, Tehran, Iran
3. Department of Oral and Maxillofacial Surgery, School of Dentistry, Tabriz University of Medical Sciences, Tabriz, Iran
4. Craniomaxillofacial Research Center, Tehran University of Medical Sciences, Tehran, Iran
5. Tehran University of Medical Sciences, Tehran, Iran

ABSTRACT

Backgrounds: Dental implants are often utilized to replace missing teeth in the maxillary posterior region. Following tooth extraction, bone grafting, and implant placement are carried out in stages. However, in medical procedures errors are inevitable; therefore, measures should be taken to address and reduce these errors in future treatments.

Methods: Implants displaced inside the maxillary sinus were reviewed to identify the best techniques for retrieving them. We conducted a comprehensive search in Scopus, PubMed, and Web of Science databases from January 2000 to January 2023. Inclusion criteria were original studies including original cohorts, case-controls, and clinical trials that evaluated methods of retrieving displaced maxillary implants.

Results: Overall, 258 publications were identified. After elimination of duplicates and those not meeting the inclusion criteria, full texts of 24 articles were reviewed. Of the 120 displaced implants, 57 were dislocated during surgery. The most common complication following implant displacement is maxillary sinusitis, which typically manifests a year post-op.

Conclusion: Displacement of implants in the maxillary sinus is a common occurrence caused by a variety of factors. Implant displacement could lead to complications in the maxillary sinuses, paranasal sinuses, and other adjacent anatomical spaces and structures.

KEYWORDS

Dental implant; dental implant displacement; Implant failure; Maxillary sinus; Treatment outcome

Please cite this paper as:

Dehghani N, Azarsina M, Mahmoudi X, Mohajeri Tehrani M, Chinian S. Factors Contributing to Dental Implants Displacement inside the Maxillary Sinus and Their Treatment: A Systematic Review. *World J Plast Surg.* 2025;14(3):1-7.

doi: 10.61186/wjps.14.3.**

INTRODUCTION

Implants in the maxillary posterior region represents a challenging procedure due to low maxillary bone density, the maxillary sinus pneumatization, and the alveolar bone loss in the edentulous region ¹. Treatment outcome depends critically on an implant's primary stability, as it can inadvertently get dislocated into the maxillary sinus via inadequate primary stability. During insertion, insufficient primary stability may also result in implant failure at a later stage of the treatment due to inadequate bone implant integration ².

*Corresponding Author:

Nima Dehghani

Department of Oral and Maxillofacial Surgery, Tehran University of Medical Sciences, Tehran, Iran

Email: nimadt2002@gmail.com

Received: ***

Accepted: ***

The maxillary arch is a sensitive site for implant placement since it is in close proximity to the maxillary sinus^{3,4}. Cases of implants displaced into the maxillary sinus during insertion or healing have been reported^{2,5}.

The patient's age and the presence of teeth determine the degree of pneumatization. The pneumatization of the maxillary may cause thinning of the alveolar bone, which might result in displacement of dental implants into the sinus cavity during implantation or installment of prosthetic restorations. Implant displacement may also occur as a result of the bite forces exerted by the implant prosthesis. This failure is observed more frequently in patients with bone graft and implant placed immediately after the sinus has been elevated⁶. The reduced height of the remaining alveolar bone should also be taken into consideration, particularly when implants are placed in bone that has a minimum height of less than four millimeters after sinus elevation bone grafting^{7,8}. The preferred option is to remove displaced implant instantly. If the procedure is postponed, sinusitis must be treated with antibacterial agents and nasal decongestant medications before the implant is

removed either by the Caldwell-Luc method or endoscopically¹.

In this study, displaced implants in the maxillary sinus were reviewed to identify the best retrieval techniques.

METHODS

Search strategy

Following the Preferred Reporting Items for Systematic Reviews and Meta-Analyses (PRISMA) guidelines (Figure 1), this systematic review and meta-analysis was conducted. We searched Scopus, PubMed, and Web of Science databases for keywords “implant” AND “maxillary” AND “removal” AND “sinus.” We included English publications from 2000 to January 2023 and used Endnote software to store and analyze the articles. We screened and selected the studies that met the requirements for inclusion by reviewing the titles, abstracts, and full text of the search results.

The inclusion criteria were original studies that evaluated the methods of restoring maxillary dental implants and the original cohort, case-control, and

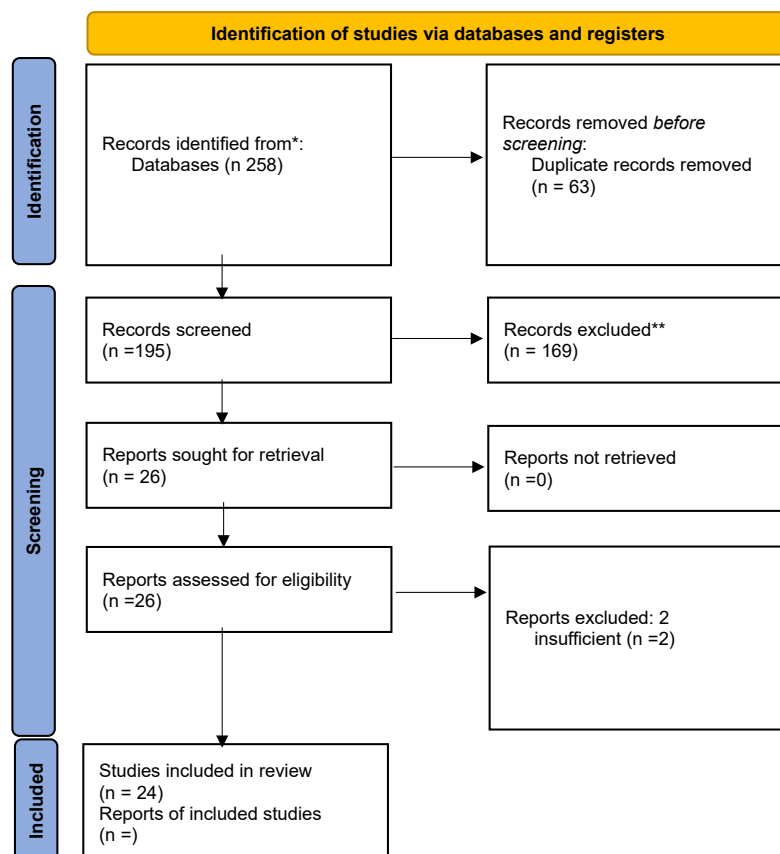


Figure 1: PRISMA 2020 flow diagram

clinical trial. The exclusion criteria were studies that reported foreign bodies or teeth, implants displaced into the other sinus, case reports, review studies, and duplicate studies. No primary human or animal research was conducted for this review, therefore IRB approval and no requirement for informed consent existed. Every study that was a part of this review underwent independent review and was approved by their respective ethical boards.

Quality Assessment and Data Extraction

We employed the Rayyan platform to screen and extract data from the studies that matched the inclusion criteria. This study used the PICO model,

where P stood for patients with implants that had become misplaced into their sinuses; I stood for retrieving misplaced implants; C stood for comparing different treatment approaches based on how time-consuming and low-complication they were; and O stood for determining the optimal approach. Two reviewers appraised the quality of the studies independently applying the nine-point Joanna Briggs Institute critical appraisal checklist for studies. If there was a disagreement, a consensus was reached. The included studies fulfilled more than 50% of the quality assessment criteria. From the studies in Table 1, we extracted data on publication year, country, number of patients, removal method,

Table 1: Perforations, management, and complications in selected studies

Study Name	Count of Implants	Duration Between Placement and Dislocation	Sinus Complication	Removal	Removal Technique	Ref
Bennard/ 2022	40	3 cases: Immediately 21 cases: 6 months 16 cases: more 6 months	Sinusitis/ Ostium obstruction/ Pain, nasal discharge	Removed	11 cases: Transnasal 25 cases: transoral 4 cases: OAF [†]	22
Safadi/ 2020	24	Immediately	Sinusitis	Removed	Transnasal	19
Márquez/ 2022	2	4 months	Facial pain	Removed	Transoral/ Transnasal	23
Sgaramella/ 2016	21	Immediately	Sinusitis	Removed	16 cases: Transoral 5 cases: CL [‡]	15
Chppuis	1	Immediately	swelling of Schneiderian membrane	Removed	Transnasal	24
Flanagan	1	Immediately	No	Removed	CL [‡]	25
Fusari	1	Immediately	No	Removed	CL [‡]	26
Raghoebar and Vissink	1	5 months	No	Removed	CL [‡] /SL [§]	27
Galindo	1	4 years	No	Not removed	-	28
Galindo Moreno	1	Before loading	No	Removed	CL [‡]	9
Lida	1	10 years	No	Removed	CL [‡]	29
Kitamura	1	3 years	Sinusitis	Removed	Transnasal	30
Kluppel	1	6 months	No	Removed	CL [‡] A [§] / SL [§]	31
Lubbe	1	3 weeks	Facial pain	Removed	CL [‡]	32
Nakamura	1	Immediately	No	Removed	Transnasal	33
Ramotar	1	Immediately	No	Removed	Transnasal	34
Ridaura- Ruiz	3	4 months	No	Removed	CL [‡]	35
Scarano	1	4 months	Sinusitis	Removed	CL [‡]	36
Tilaveridis	1	Immediately	No	Removed	CL [‡]	37
Ucer	1	8 weeks	No	Removed	Transoral Endoscopy + SL [§]	38
Galindo- Moreno	1	13 months	Yes	Removed	-	39
Borgonovo	1	6 months	swelling of Schneiderian membrane	Removed	CL [‡] /A [§]	40
Guler and Delilbasi	1	Immediately	No	Removed	CL [‡]	41
El Charkawi	1	Immediately	Sinusitis	Removed	Transoral Endoscopy	42

†OAF, oroantral fistula; ‡CL, Caldwell-Luc approach; §A, antrostomy; ¶SL, sinus lift with bone graft

Table 2: Sinusitis treatment methods

Oroantral Fistula	Complication			Suggested Method of removal
	Ostium Obstruction	Sinusitis	Paranasal Sinus Affected	
-	+	+	+	Transnasal endoscopy
-	-	+	-	Transoral endoscopy
+	-	±	-	Caldwell- Luc approach

time interval between insertion and displacement, and sinus complications. Lastly, we extracted information regarding publication year, research topic, study design, number of implants, period between implantation and dislocation, sinus complication, and the removal method.

Statistical Analysis

SPSS 28.0 software (IBM Corp., Armonk, NY, USA) was used for analysis. We performed Pearson's chi-square test to compare subgroups for each factor (follow-up duration, bone graft implantation, implant length, residual bone height). We established the significance level at $P = 0.05$. We also computed odd ratios (ORs) and 95% confidence intervals (CIs).

RESULTS

Search Outcome and Study Characteristics

A thorough search in Scopus, PubMed, and Web of Science databases was conducted. Overall, 258 publications that met the PICO (Patient, Intervention, Comparison, Outcome) framework of this study were selected. We then deleted duplicates and removed articles that did not meet our inclusion and exclusion criteria. The full text of the 24 remaining articles including retrospective, prospective, case-control, and cohort studies were examined (Figure 1).

The majority of displacements into the maxillary sinus occurred during the placement of implants, however they resulted few complications, such as maxillary sinusitis. Among all the cases, the time of the dislocation into the maxillary sinus for 109 implants were indicated. Among those 57 were dislocated during insertion. Others were predominantly displaced within one year after the implant insertion. Galindo-Alvarez et al. demonstrated that implants were primarily displaced after loading, according to a comparison of displacement before and after loading (Ten versus

five)⁹. Most displaced implants (34 of 49) did not cause any complications. Thirty seven implants were extracted: four through trans nasal endoscopy, three through the transoral approach, and 29 through the Caldwell-Luc technique. No attempt was made to remove twelve implants Because of the patient's disinterest, lack of symptoms, or internal displacement in the digestive system (Table 1).

Chiapasco et al. found that in five of thirteen patients with sinusitis, who also had maxillary ostial occlusion, an oral method with FESS was utilized¹⁰. Moreover, they stated that an oral method alone may be effective when there is a fistula in the oroantral region or sinusitis that does not affect the ostium. Regardless of the method used to remove the implant, the recurrence of maxillary sinusitis was one of the many complications. In conclusion, a trans-nasal endoscopy is recommended when the ostium is obstructed, or the paranasal sinus requires treatment. However, the Caldwell-Luc method can be applied by itself or with an endoscopy in the presence of an oroantral fistula. Endoscopy is applicable when maxillary sinusitis exists, yet a thorough examination prior to surgery is necessary to determine the appropriate method (Table 2).

DISCUSSION

Due to maxilla's poor bone structure, pneumatized sinuses, and loss of alveolar bone in the absence of dentition, implant-based restoration for maxillary posterior teeth is challenging¹. When there is inadequate primary stability during implant placement or when the implant is not properly integrated into the bone after implantation, a maxillary implant may inadvertently dislocate into the maxillary sinus¹¹. While some implant displacements do not present symptoms, others may cause complications, such as maxillary sinusitis or migrating into the paranasal sinus². This study describes the mechanisms of dislocation, potential complications, and implant retrieval procedures in

accordance with the time of implant displacement. Implant displacement can lead to infection, as indicated by swelling. A dislocated implant may contribute to adverse consequences for surrounding tissues and organs². Ethmoid sinuses, orbital floors, sphenoid sinuses, and even the cranial fossa might be affected by implant displacement into the maxillary sinus^{2, 12}. Implants that have caused sinusitis must be removed, and the healing of the sinus depends upon the ostium of the maxilla being opened¹³. As a result of sinusitis, transnasal surgery with functional endoscopic sinus surgery (FESS) is performed to accomplish the following: retrieving foreign bodies, removing obstructions and narrowed orifices, and treating hyperplastic, hypertrophic, or infected mucosa².

We found that eight studies had their implants removed right away; one study had its implants removed before it was loaded, two studies had their displaced implants removed in a matter of weeks, six studies in a matter of months, and three studies had their implants removed in a matter of years. The removal of dislocated implants ought to happen right away to stop late sinusitis caused by foreign bodies in the sinus cavity¹⁴. Furthermore, in this investigation, most of the studies removed the implant using the Caldwell-Luc (CL) technique, with the transnasal technique coming in second. The CL approach facilitates the removal of objects that are not suitable for endoscopic removal, either because of their size or because of excessive displacement thanks to the provided extensive view¹⁵. The CL approach could be employed in situations where an endoscopy failed, or chronic sinusitis is refractory¹⁶. Several articles, however, suggest using endoscopic surgery for the removal of displaced implants; since it is less invasive than the CL method and less likely to cause excessive damage to the maxillary sinus mucosa, it reduces wounds or bleeding in the mucosa, accelerates healing, and preserves the mucosa^{2, 17, 18}. Endoscopic retrieval of implants with significant anteromedial dislocation provides greater ease of access than intraoral retrieval via the paranasal sinus².

Moreover, if the displacement of the implant has resulted in an oroantral fistula, it is necessary to repair the fistula transorally^{2, 19}. Furthermore, antrostomy has also been reported as an effective treatment for maxillary sinusitis^{15, 19}. Moreover, this technique is considered a good option when

it is difficult to achieve mucosal clearance and it is impossible to remove the implant solely through the CL procedure²⁰. González-García et al. suggest trans oral endoscopy and CL surgery are appropriate forms of treatment if ostium treatment is not necessary and paranasal sinuses are unaffected²¹. An endoscopy and transoral method are recommended in oroantral fistula cases.

CONCLUSION

Implant displacement in the maxillary sinus is frequent and can be caused by several factors. It is possible for implant displacement to lead to complications within the maxillary sinuses, paranasal sinuses, and other nearby areas. It is recommended that patients should undergo a thorough evaluation before selecting a treatment method to treat this condition. Since the choice of any treatment is highly dependent on the condition of the patient, it is neither possible nor appropriate to suggest a specific course of treatment for all cases.

ACKNOWLEDGEMENTS

No financial support was received for this study.

CONFLICT OF INTEREST

The authors declare that there are no conflicts of interest regarding this study.

REFERENCES

1. M. King E, Schofield J. Restoratively driven planning for implants in the posterior maxilla-Part 1: alveolar bone healing, bone assessment and clinical classifications. *Br Dent J* 2023;235(8):585-92.
2. Jeong K-I, Kim S-G, Oh J-S, You J-S. Implants displaced into the maxillary sinus: a systematic review. *Implant Dent* 2016;25(4):547-51.
3. Miyazawa K, Shibata M, Tabuchi M, Kawaguchi M, Shimura N, Goto S. Optimal sites for orthodontic anchor screw placement using panoramic images: risk of maxillary sinus perforation and contact with adjacent tooth roots during screw placement. *Prog Orthod* 2021;22:1-8.
4. Mohajerani H, Poorian B, Dehghani N, Bemanali M. The Implant Stability Quotient and Randomized Clinical Trial for ISQ Value Change Pattern. *Int J Rev Life Sci* 2015;5:469-79.
5. Gnigou M, Goutzani L, Sarivalasis S, Petsinis V. Retrieval of displaced implants inside the maxillary sinus: two case reports and a short review. *Int J Implant Dent* 2019;5:1-8.
6. An J-H, Park S-H, Han JJ, et al. Treatment of dental

- implant displacement into the maxillary sinus. *Maxillofac Plast Reconstr Surg* 2017;**39**:1-5.
7. Al-Moraissi EA, Altairi NH, Abotaleb B, Al-Iryani G, Halboub E, Alakhali MS. What is the most effective rehabilitation method for posterior maxillas with 4 to 8 mm of residual alveolar bone height below the maxillary sinus with implant-supported prostheses? A frequentist network meta-analysis. *J Oral Maxillofac Surg* 2019;**77**(1):70. e1-. e33.
 8. Dehghani N, Azarsina M, Mahmoudi X, Barani R, Hassantash S, Manouchehri N. Investigating Effective Factors in Maxillary Sinus Membrane Rupture and Its Treatment Methods: A Review. *Journal of Craniomaxillofacial Research* 2024:138-45.
 9. Galindo-Moreno P, Padial-Molina M, Avila G, Rios HF, Hernández-Cortés P, Wang HL. Complications associated with implant migration into the maxillary sinus cavity. *Clin Oral Implants Res* 2012;**23**(10):1152-60.
 10. Chiapasco M, Felisati G, Maccari A, Borloni R, Gatti F, Di Leo F. The management of complications following displacement of oral implants in the paranasal sinuses: a multicenter clinical report and proposed treatment protocols. *Int J Oral Maxillofac Surg* 2009;**38**(12):1273-8.
 11. Seigneur M, Hascoet E, Chaux A-G, Lesclous P, Hoornaert A, Cloitre A. Characteristics and management of dental implants displaced into the maxillary sinus: a systematic review. *Int J Oral Maxillofac Surg* 2023;**52**(2):245-54.
 12. Mehra P, Murad H. Maxillary sinus disease of odontogenic origin. *Otolaryngol Clin North Am* 2004;**37**(2):347-64.
 13. Kim SJ, Park JS, Kim HT, Lee CH, Park YH, Bae JH. Clinical features and treatment outcomes of dental implant-related paranasal sinusitis: A 2-year prospective observational study. *Clin Oral Implants Res* 2016;**27**(11):e100-e4.
 14. Hamdoon Z, Mahmood N, Talaat W, et al. Evaluation of different surgical approaches to remove dental implants from the maxillary sinus. *Sci Rep* 2021;**11**(1):4440.
 15. Sgaramella N, Tartaro G, D'Amato S, Santagata M, Colella G. Displacement of dental implants into the maxillary sinus: a retrospective study of twenty-one patients. *Clin Implant Dent Relat Res* 2016;**18**(1):62-72.
 16. Cutler JL, Duncavage JA, Matheny K, Cross JL, Miman MC, Oh CK. Results of Caldwell-Luc after failed endoscopic middle meatus antrostomy in patients with chronic sinusitis. *The Laryngoscope* 2003;**113**(12):2148-50.
 17. Chang P-H, Chen Y-W, Huang C-C, Fu C-H, Huang C-C, Lee T-J. Removal of displaced dental implants in the maxillary sinus using endoscopic approaches. *Ear Nose Throat J* 2021;**100**(10_suppl):995S-8S.
 18. Murase Y, Yoshida S, Kishimoto K, Shimizu R, Ibaragi S, Sasaki A. The Transoral Endoscope-Assisted Approach for Removal of a Dental Implant Displaced into the Maxillary Sinus: A Case Report and Review of the Literature. *J Maxillofac Oral Surg* 2022;**21**(2):639-47.
 19. Safadi A, Ungar O, Oz I, Koren I, Abergel A, Kleinman S. Endoscopic sinus surgery for dental implant displacement into the maxillary sinus—a retrospective clinical study. *Int J Oral Maxillofac Surg* 2020;**49**(7):966-72.
 20. Tsodoulos S, Karabouta I, Voulgaropoulou M, Georgiou C. Atraumatic removal of an asymptomatic migrated dental implant into the maxillary sinus: a case report. *J Oral Implantol* 2012;**38**(2):189-93.
 21. González-García A, González-García J, Diniz-Freitas M, García-García A, Bullón P. Accidental displacement and migration of endosseous implants into adjacent craniofacial structures: a review and update. *Med Oral Patol Oral Cir Bucal* 2012;**17**(5):e769.
 22. Bennardo F, Barone S, Buffone C, Colangeli W, Antonelli A, Giudice A. Removal of dental implants displaced into the maxillary sinus: a retrospective single-center study. *Head Face Med* 2022;**18**(1):34.
 23. Núñez-Márquez E, Salgado-Peralvo A-O, Peña-Cardelles J-F, Kewalramani N, Jiménez-Guerra A, Velasco-Ortega E. Removal of a migrated dental implant from a maxillary sinus through an intraoral approach: A case report. *J Clin Exp Dent* 2021;**13**(7):e733.
 24. Chappuis V, Suter VG, Bornstein MM. Displacement of a dental implant into the maxillary sinus: report of an unusual complication when performing staged sinus floor elevation procedures. *Int J Periodontics Restorative Dent* 2009;**29**(1).
 25. Flanagan D. A method to retrieve a displaced dental implant from the maxillary sinus. *J Oral Implantol* 2009;**35**(2):70-4.
 26. Fusari P, Doto M, Chiapasco M. Removal of a dental implant displaced into the maxillary sinus by means of the bone lid technique. *Case Rep Dent* 2013;**2013**.
 27. Raghoebar GM, Vissink A. Treatment for an endosseous implant migrated into the maxillary sinus not causing maxillary sinusitis: case report. *Int J Oral Maxillofac Implants* 2003;**18**(5).
 28. Galindo P, Sánchez-Fernández E, Avila G, Cutando A, Fernandez JE. Migration of implants into the maxillary sinus: two clinical cases. *Int J Oral Maxillofac Implants* 2005;**20**(2).
 29. Iida S, Tanaka N, Kogo M, Matsuya T. Migration of a dental implant into the maxillary sinus: a case report. *Int J Oral Maxillofac Implants* 2000;**29**(5):358-9.

30. Kitamura A. Removal of a migrated dental implant from a maxillary sinus by transnasal endoscopy. *Br J Oral Maxillofac Surg* 2007;**45**(5):410-1.
31. Kluppel LE, Santos SE, Olate S, Freire Filho FWV, Moreira RWF, de Moraes M. Implant migration into maxillary sinus: description of two asymptomatic cases. *Oral Maxillofac Surg* 2010;**14**:63-6.
32. Lubbe D, Aniruth S, Peck T, Liebenberg S. Endoscopic transnasal removal of migrated dental implants. *Br Dent J* 2008;**204**(8):435-6.
33. Nakamura N, Mitsuyasu T, Ohishi M. Endoscopic removal of a dental implant displaced into the maxillary sinus. *Int J Oral Maxillofac Surg* 2004;**33**(2):195-7.
34. Ramotar H, Jaberoo M, Ng NK, Pulido M, Saleh H. Image-guided, endoscopic removal of migrated titanium dental implants from maxillary sinus: two cases. *J Laryngol Otol* 2010;**124**(4):433-6.
35. Ridaura-Ruiz L, Figueiredo R, Guinot-Moya R, et al. Accidental displacement of dental implants into the maxillary sinus: a report of nine cases. *Clin Implant Dent Relat Res* 2009;**11**:e38-e45.
36. Scarano A, Perrotti V, Carinci F, Shibli JA. Removal of a migrated dental implant from the maxillary sinus after 7 years: A case report. *Oral Maxillofac Surg* 2011;**15**:239-43.
37. Tilaveridis I, Lazaridou M, Dimitrakopoulos I, Lazaridis N, Charis C. Displacement of three dental implants into the maxillary sinus in two patients. Report of two cases. *Oral Maxillofac Surg* 2012;**16**:311-4.
38. Ucer TC. A modified transantral endoscopic technique for the removal of a displaced dental implant from the maxillary sinus followed by simultaneous sinus grafting. *Int J Oral Maxillofac Implants* 2009;**24**(5).
39. Galindo-Moreno P, Padial-Molina M, Sánchez-Fernández E, Hernández-Cortés P, Wang H-L, O'Valle F. Dental implant migration in grafted maxillary sinus. *Implant Dent* 2011;**20**(6):400-5.
40. Borgonovo A, Fabbri A, Boninsegna R, Dolci M, Censi R. Displacement of a dental implant into the maxillary sinus: case series. *Minerva Stomatol* 2010;**59**(1-2):45-54.
41. Guler N, Delilbasi C. Ectopic dental implants in the maxillary sinus. *Quintessence Int.* 2007;**38**(5).
42. El Charkawi HG, El Askary AS, Ragab A. Endoscopic removal of an implant from the maxillary sinus: a case report. *Implant Dent* 2005;**14**(1):30-5.