Case Report

Successful Replantation of Total Scalp Avulsion: A Case Report and Literature Review

Mohammad Reza Akhoondi Nasab [1], Alireza Minouee [1*], Mohammad Hossein Shariat [1]

1. Department of Plastic Surgery, Fatima Zahra Hospital, Iran University of Medical Sciences, Tehran, Iran

***Corresponding Author:**

Alireza Minouee MD

Department of Plastic Surgery, Fatima Zahra Hospital, Iran University of Medical Sciences, Tehran, Iran

Tel.: +989113534380
Email: alireza_minouee@yahoo.com

Received: 7/14/2025
Accepted: 10/11/2025

ABSTRACT

This case report describes the surgical management and outcome of a 24-year-old female engineer who suffered a total scalp avulsion injury caused by an industrial food mixer. The injury extended from the level of the eyebrows to the back of her neck and was complicated by the traumatic amputation of her right-hand first finger. Successful replantation of the scalp was achieved using microsurgical techniques, with postoperative challenges including venous congestion requiring secondary intervention. This case highlights the importance of timely surgical intervention, comprehensive trauma management, and postoperative anticoagulation in extensive avulsion injuries.

KEYWORDS
Scalp; Avulsion; Replantation; Microsurgery

Please cite this paper as:
Akhoondi Nasab MR, Minouee A, Shariat MH. Successful Replantation of Total Scalp Avulsion: A Case Report and Literature Review. World J Plast Surg. 2025;14(3):91-96.
doi: 10.61882/wjps.14.3.91

INTRODUCTION

Scalp avulsion injuries are rare but devastating events that typically result from high-energy trauma, such as industrial accidents. Most patients are women because of the entrapment of long hair in high-speed rotating machinery [1]. The complexity of these injuries increases when accompanied by other traumatic injuries, such as head and neck trauma, massive bleeding and amputations, which could be potentially life-threatening [2]. Before the advent of microvascular surgery with the invention of microscope in the 20th century, avulsed tissues including scalp were not replantable, and the exposed calvarium was repaired with simple skin grafting which often led to permanent baldness [3,4]. Replacing the avulsed scalp as a free graft and suturing it in place showed disappointing results, with the exception of one case with a partially avulsed scalp [5].

It was not until decades later in 1976 when Miller et al reported the first successful scalp replantation by using multiple superficial temporal vessels [6]. Reports by Nguyen [7] and Nahai et al [8] showed that scalp replantation is also possible with just one arterial anastomosis along with at least one vein anastomosis to achieve excellent aesthetic

[Downloaded from wjps.ir on 2026-11-25]

[DOI: 10.61882/wjps.14.3.91]

results. Although replantation is challenging for reconstructive surgeons, many successful revascularization reports have shown that recent advances in microsurgery have enabled replantation to become the treatment of choice for this kind of injuries [9]. Timely intervention and meticulous microsurgical technique are paramount for achieving favorable outcomes.

This report presents a case of extensive scalp avulsion and digit amputation, detailing the surgical approach, postoperative challenges, and outcomes.

CASE PRESENTATION

Ethical approval and Informed consent

Informed consent was obtained from the patient and her spouse for the publication of this case report, and all ethical considerations were respected.

A 24-year-old woman working as an engineer in an industrial food company sustained a traumatic scalp avulsion while inspecting a mixer machine. Her hair became entangled in the machine, pulling her scalp into the mixer. As she struggled to free herself, her right-hand first finger was also amputated.

The avulsed scalp which was brought in saline soaked gauze extended from the eyebrows and nasal bridge to the back of the neck (Figure 1), and the amputated finger was severely mangled and deemed unsalvageable.

The Avulsion plane was from loose areolar tissue in subgaleal layer (i.e., the plane between frontalis muscle and the periosteum) except for the occipital and eyebrow regions which were avulsed from the more superficial subcutaneous layer (Figure 2).



Figure 1: Patient on arrival in the ER, (A) frontal, (B) occipital and (C) lateral views showing extensive scalp avulsion from above the eyebrows and nasal dorsum to the back of the patient's neck in occipital area. (D) Avulsed scalp on the back table. ER: Emergency Room

[Downloaded from wjps.ir on 2026-11-25]

[DOI: 10.61882/wjps.14.3.91]

Approximately four hours post-injury, the patient arrived at the hospital, hemodynamically stable but in significant distress. The avulsed scalp was preserved and transported with the patient. After initial triage and stabilization, she was taken to the operating room for emergent replantation.

Surgical Intervention

Under general anesthesia, the avulsed scalp was thoroughly debrided and prepared for reattachment. Microsurgical reconstruction was performed, utilizing the right side superficial temporal artery and vein as the recipient vessels for revascularization (Figure 3). The left superficial temporal vessels was severely damaged and unsuitable as recipients so just one artery and vein was used for replantation. Anastomosis was done using 10-0 Ethicon PROLENE and ZEISS surgical microscope in an end to end simple interrupted manner. The surgical team meticulously ensured alignment of the scalp's edges and achieved an adequate blood supply to the replanted tissue in a 6 hours long operation.

Given the complexity of the trauma, the amputation site on the right hand was cleaned and closed primarily.

Postoperative Course

Postoperatively, the patient was started on a therapeutic dose of intravenous heparin to promote microvascular perfusion and prevent thrombosis and transferred to intensive care unit for close observation and hourly flap monitoring. On the first postoperative day, she developed venous congestion in the replanted scalp. This prompted an urgent return to the operating room for venous revision, which revealed venous thrombosis so revision of the venous anastomoses were established to improve outflow, successfully resolving the congestion. In the senior author's opinion the cause of thrombosis was excessive tension on the vein due to weight of the flap that displaced it away from the anastomosis site, which was handled by releasing the skin over the vessel and securing the flap properly so no



Figure 2: Interior view of the avulsed scalp showing subcutaneous plane of avulsion in the occipital and eyebrow regions

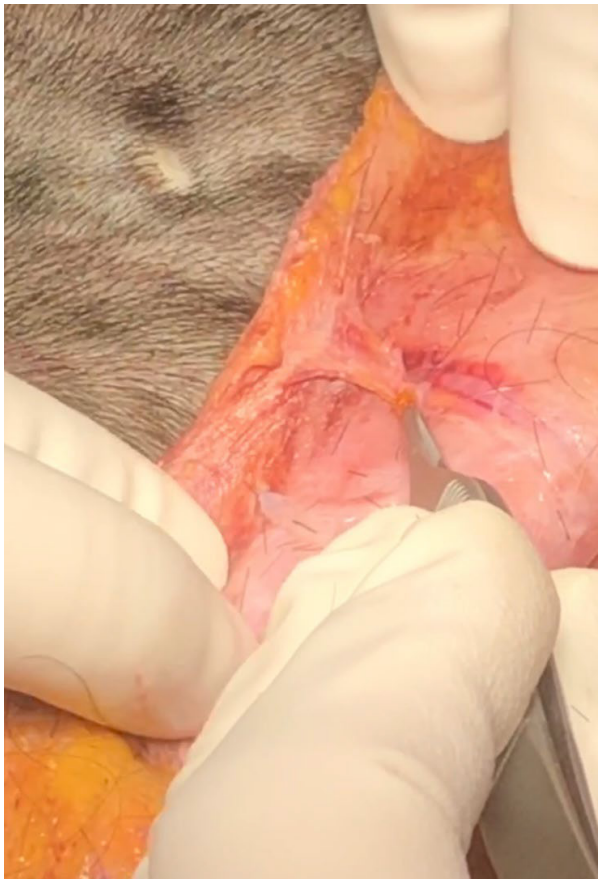

Figure 3: Right side superficial temporal vessels were selected and prepared for anastomosis

[Downloaded from wjps.ir on 2026-11-25]

[DOI: 10.61882/wjps.14.3.91]

further vein graft was needed. The patient remained in the hospital for close monitoring. Over the following days, the scalp showed signs of adequate perfusion, with no evidence of necrosis or infection. The amputation site healed uneventfully. She was discharged on postoperative day 6 with detailed instructions for anticoagulation therapy including daily single daily dose of ASA 80, wound care, and follow-up. On follow up visit the week after discharge there was some degree of superficial skin necrosis mostly containing the epidermal layer in the eyebrows and occipital areas, because there was no sign of infection or discharge from the wound, we decided to manage this complication conservatively with local wound care. One month after the operation the scalp had good perfusion with signs of hair growing back (Figure 4).

After 3 months, the demarcated necrotic tissues on supraorbital and occipital areas were debrided and repaired with split thickness skin graft from anterior thigh region (Figure 5). Interestingly despite not repairing any nerves in the original operation, the scalp's protective sensation began to return 3 months post injury and continued to improve. The patient is still on long term follow up



Figure 4: The patient one month after replantation showing signs of her hair growing back with acceptable cosmetics and minimal dry necrosis in left supraorbital region



Figure 5: The patient five months after replantation and skin grafting of the necrotic areas on frontal and occipital regions. Hair has grown back with some visible scars which are planned for revision

[Downloaded from wjps.ir on 2026-11-25]

[DOI: 10.61882/wjps.14.3.91]

for sensory recovery as we were unable to repair the avulsed nerves because of severe damage and defect. Although the results are acceptable, there is plans for secondary reconstruction by tissue expansion and skin advancement to achieve better cosmetics in the aforementioned necrotic areas.

DISCUSSION

Whenever possible every attempt should be made to replant the avulsed scalp, since it's a unique tissue and there is nothing that could replace it [1,2,3]. From the aesthetic point of view other substitutes like skin grafts or free tissue transfer simply cannot bear hair [11]. Almoshantaf et al reported coverage of a large scalp defect with full thickness skin graft harvested from anterior thigh region, which healed well despite complete loss of hair and sensation [12].

This case illustrates the challenges of managing complex injuries involving extensive scalp avulsion and digit amputation. Timely microsurgical intervention is essential for ensuring tissue viability in scalp avulsion injuries, with the superficial temporal artery and vein serving as reliable vessels for revascularization. Nguyen In his series of seven replanted scalps emphasizes on ischemic time for success of the procedure [7].

The use of therapeutic anticoagulation with intravenous heparin also not completely preventive but is critical in such cases to maintain vascular patency and reduce the likelihood of thrombotic complications. Venous congestion is a common issue in scalp replantation [9,10], as observed here. Secondary venous revision often becomes necessary and can significantly improve outcomes. Without venous drainage the replantation will almost always fail as Yin et al reported [13].

The blood supply of the forehead and scalp is robust and consists of the paired supraorbital, supratrochlear, superficial temporal, posterior auricular and occipital vessels. The superficial temporal vessels are most commonly used [11].

The Bunke Clinic reports the largest contemporary experience with scalp replantation, documenting a 92% success rate after 33 replants over 36 years [10], But in the literature, There is no consensus on the ideal number of required vessels to ensure success of the replantation, as scalp avulsions are not very common and the number of reported cases is limited. Some authors like cheng et al advocate to repair as many vessels as possible [1,3,6], while others like Kim et al and Nguyen suggest that only one artery and vein is enough [7,9]. Here, we managed to successfully replant a large avulsed scalp with just one artery and vein and believe it's among the few reported successful cases in Iran and the only one in our own center in the past years.

Interestingly the areas which was complicated by necrosis was the exact areas that were avulsed from subcutaneous layer not the loose areolar tissue deep to the galea aponeurosis, this shows the importance of intact vascular network for successful replantation of the scalp which runs in the subcutaneous layer and since most scalp avulsions are in the sub galea's plane this network remains perfectly intact and helps in the survival of the replanted tissue [11].

Regarding the sensory function of the replanted scalps, there are some reports on spontaneous sensory regain by nerve ingrowth after six months [2,9], we can confirm that because the same finding was observed in our patient.

The additional trauma of finger amputation underscores the need for a multidisciplinary approach in managing complex industrial injuries. Although the amputation was not salvageable, early debridement and wound closure prevented complications and facilitated recovery.

LIMITATIONS

This case report is limited by its single-case design and relatively short follow-up duration (5 months). Longer-term data on sensory recovery, hair regrowth, and cosmetic outcome will be reported in future follow-up.

CONCLUSION

This case demonstrates the successful management of a complex industrial injury involving extensive scalp avulsion and digit amputation. Early intervention, comprehensive trauma care, advanced surgical expertise and vigilant postoperative monitoring were crucial in achieving a favorable outcome. This case underscores the need for rapid and coordinated surgical and medical efforts in managing such severe injuries. We observed that the loose areolar tissue in the scalp can be of great benefit for the patient as avulsions almost always occur within this layer resulting in preservation

[Downloaded from wjps.ir on 2026-11-25]

[DOI: 10.61882/wjps.14.3.91]

of the vast vascular network and collateral vessels which run in the subcutaneous layer. This network is essential to guarantee adequate perfusion of the scalp. Also we found that despite some previous reports which advocated for repairing as many vessels as possible, survival of a large complex tissue like scalp is possible based on single artery and venous anastomosis. Although not a very common type of injury and having success in just one case is not attributable to all clinical scenarios and patients but we strongly recommend that every attempt should be made for replantation in scalp avulsions as any other treatment from simple skin grafting to complex multi-stage free flap reconstruction will not substitute the look and function of the original scalp for the patient, unless the amputated tissue is severely damaged and not salvageable.

ACKNOWLEDGMENTS

The authors thank the surgical and nursing staff at Fatima Zahra Hospital for their contributions to the successful management of this case.

CONFLICTS OF INTEREST

The authors declare no conflicts of interest.

REFERENCES

1. Wechselberger G, Pumberger P, Schwaiger K, Wimbauer J, Köninger F, Russe E, et al. Microsurgical scalp replantation: lessons learned and technical considerations. *Plast Reconstr Surg Glob Open* 2022 Mar 30;**10**(3):e4155. doi: 10.1097/GOX.0000000000004155. eCollection 2022 Mar.
2. Madsen CB, Poulsen L, Bakholdt V, et al. Microsurgical replantation of a traumatic total scalp avulsion. *BMJ Case Rep CP* 2023;**16**:e252570. doi: 10.1136/bcr-2022-252570.
3. Cheng K, Zhou S, Jiang K, Wang S, Dong J, Huang W, et al. Microsurgical replantation of the avulsed scalp: report of 20 cases. *Plast Reconstr Surg* 1996 May;**97**(6):1099–106; discussion 1107–8. doi: 10.1097/00006534-199605000-00001.
4. Neligan PC, Gurtber CG, Pusic AL. *Plastic Surgery 5th ed*. Philadelphia: Elsevier; 2023. Vol. **1**. p. 414–41.
5. Lu MM. Successful replacement of avulsed scalp. Case report. *Plast Reconstr Surg* 1976;**58**:133–6. doi: 10.1097/00006534-196903000-00002.
6. Miller GD, Anstee EJ, Snell JA. Successful replantation of an avulsed scalp by microvascular anastomoses. *Plast Reconstr Surg* 1976 Aug;**58**(2):133–6. doi: 10.1097/00006534-197608000-00001.
7. Nguyen HH. The microsurgical replantation of seven complete scalp avulsions: is one artery sufficient? *J Plast Reconstr Aesthet Surg* 2012 Dec;**65**(12):1639–44. doi: 10.1016/j.bjps.2012.06.001. Epub 2012 Jul 6.
8. Nahai F, Hurteau J, Vasconez LO. Replantation of an entire scalp and ear by microvascular anastomoses of only 1 artery and 1 vein. *Br J Plast Surg* 1978;**31**:339–42. doi: 10.1016/s0007-1226(78)90122-4.
9. Kim D, Oh S, Jeong WS. Successful replantation of an avulsed frontal scalp through microvascular anastomoses of only one artery and one vein: a case report. *Arch Craniofac Surg* 2024 Apr;**25**(2):95–8. doi: 10.7181/acfs.2023.00122.
10. Herrera F, Buntic R, Brooks D, Buncke G, Antony AK. Microvascular approach to scalp replantation and reconstruction: a thirty-six year experience. *Microsurgery* 2012 Nov;**32**(8):591–7. doi: 10.1002/micr.22037. Epub 2012 Aug 18.
11. Neligan PC, Losee JE, Hopper RA. *Plastic Surgery 5th ed*. Philadelphia: Elsevier; 2023. Vol. **3**. p. 39–51.
12. Almoshantaf MB, Swed S, Hajjar A, Alshawaf A, Nabhan A, Zetani B, et al. Successful management of scalp avulsion with full-thickness graft. *Clin Case Rep* 2022 Jul 25;**10**(7):e6094. doi: 10.1002/ccr3.6094.
13. Yin JW, Matsuo JM, Hsieh CH, Yeh MC, Liao WC, Jeng SF. Replantation of total avulsed scalp with microsurgery: experience of eight cases and literature review. *J Trauma* 2008 Mar;**64**(3):796–802. doi: 10.1097/TA.0b013e3180341fdb.

[Downloaded from wjps.ir on 2026-11-25]

[DOI: 10.61882/wjps.14.3.91]