Original Article

Comparing the Effects of Mitomycin-C and Triamcinolone-Acetonide Injections on Hypertrophic Scars and Keloids in Burn Patients

Jafar Jafarzadeh[1, 2], Mahtab Farhadi[1, 2], Nasrin Khodadadi[1, 2], Elham Farhadi[3], Abdulreza Sheikhi[1, 2*]

1. Department of Plastic Surgery, Taleghani Burn Hospital, Ahvaz Jundishapur University of Medical Sciences, Ahvaz, Iran
2. Clinical Research Development Unit, Taleghani Burn Hospital, Ahvaz Jundishapur University of Medical Sciences, Ahvaz, Iran
3. Clinical Research Development Unit, Golestan Hospital, Ahvaz Jundishapur University of Medical Sciences, Ahvaz, Iran

***Corresponding Author:**

Abdulreza Sheikhi, MD

Assistant Professor of Plastic Surgery, Department of Plastic Surgery, Taleghani Burn Hospital, Ahvaz Jundishapur University of Medical Sciences, Ahvaz, Iran.

Email: sheikhi-a@ajums.ac.ir

Received: 9/20/2025
Accepted: 11/1/2025

ABSTRACT

Background: Hypertrophic scars (HTS) and keloids are the proliferative responses of the fibroblastic. Surgical excision lead to changes, but postoperative recurrence rate seems to be still high. The topical use of mitomycin C (MMC) has been thus documented to suppress fibroblast proliferation. We aimed to investigate the effects of MMC injection on HTS and keloids in burn wounds, and compare the results with intralesional Triamcinolone Acetonide (TAC) injection in with regard to scar size reduction.

Methods: This randomized clinical trial was conducted on 90 burn patients (divided into two groups) with hypertrophic scars and keloids at Taleghani Burn Hospital, Ahvaz, Iran, in 2023. Patients were randomly assigned to receive intralesional MMC (0.4 mg/dL) or TAC (0.4 mg/dL). Scar characteristics were assessed pre- and post-treatment using the Vancouver Scar Scale (VSS) over six months.

Results: The average size of the scars at the pre- and post-intervention stages was 15.71 and 4.81 mm. No significant difference was observed between both groups. Effect of MMC was over and above TAC. There was a significant difference between both groups. Significant difference was found between the Vancouver Scar Scale (VSS) mean scores before and after the intervention, so the TAC value was greater than that of MMC, and the scores at the pre- and post-intervention stages were significantly different.

Conclusion: MMC and TAC were considered as effective methods for HTS and keloid management. In spite of this, the VSS scores and the scar size denoted that MMC was much more effective in the treatment of such scars than TAC.

KEYWORDS
Mitomycin-C; Triamcinolone-Acetonide; Keloids; Hypertrophic Scar

Please cite this paper as:
Jafarzadeh J, Farhadi M, Khodadadi N, Farhadi E, Sheikhi A. Comparing the Effects of Mitomycin-C and Triamcinolone-Acetonide Injections on Hypertrophic Scars and Keloids in Burn Patients. World J Plast Surg. 2025;14(3):70-78.
doi: 10.61882/wjps.14.3.70

[Downloaded from wjps.ir on 2026-11-25]

[DOI: 10.61882/wjps.14.3.70]

INTRODUCTION

Hypertrophic scars (HTS) and keloids usually develop once the scar tissues are laid open to the excessive deposition of collagen bands in wounds. Other than cosmetic skin problems, HTS and keloids frequently lead to itching, pain, and psychological stress. Even though such scars are assumed different, their physiology is the same thing, since both are essentially the deposition of collagen bands in the dermis and the hypodermis, as the subcutaneous tissue.

The root cause of HTS and keloids has yet remained unaccounted. Nevertheless, this type of skin disorder more commonly occurs during some skin trauma incidents, e.g., hyperelastic skin stretches, foreign body reactions (FBRs) in the skin, and chronic wounds. Considering some individual characteristics, such as the genetic ones, they also appear much more particularly for the period of puberty and menopause and even on dark skin [1].

HTS and HTS can induce some complications, including tenderness, itching, low quality of life, as well as psychological and social problems among patients. Proper treatment accordingly involves the topical or intralesional injections of steroids [2].

Chemotherapy, silicone gel application, low-dose radiation therapy, pulsed dye laser treatment, high dose-rate (HDR) brachytherapy, imiquimod topical use, along with bleomycin, intralesional 5-fluorouracil (5-FU), interferon alfa-2b, and tacrolimus injections, and multimodal treatments can also bring their own outcomes [3]. In this vein, mitomycin-C (MMC) is known as an antineoplastic antibiotic to inhibit cell proliferation through obstructing deoxyribonucleic acid (DNA) replications [4].

Of note, the fibroblast proliferation instigates the processes of protein and collagen synthesis, and then angiogenesis arises. Previous research has thus far demonstrated a downward trend in the proliferation of fibroblasts subjected to MMC to control such cells, and then treat keloids and HTS [5].

It has been concluded the MMC injection of 0.4 mg/dl in HTS and keloids can prevent their recurrence thanks to its inhibitory action. Given the side effects of MMC on healthy tissues, the United States Food and Drug Administration (FDA) has accordingly advocated the concentration of 0.4 mg/dl for this agent [6]. Upon selecting the target population in the present study and measuring the scar size, almost after one year, the intralesional injection of MMC (0.4 mg/dl) was initially performed in the scar site, then the patients were evaluated after a six-month interval in terms of the scar size, and finally compared with the scar size of other sites injected with steroid (here, triamcinolone-acetonide; TAC).

MATERIALS AND METHODS

Study design and ethical considerations

This study was conducted in accordance with the ethical principles of the Declaration of Helsinki (DoH). It was also approved by the Ethics Committee of Ahvaz Jundishapur University of Medical Sciences, Ahvaz, Iran. The Institutional Ethics Committee at Ahvaz Jundishapur University of Medical Sciences, Ahvaz, Iran, further agreed to all study protocols (with the code no. IR.AJUMS.HGOLESTAN.REC.1401.129). As well, informed written consent was obtained from all participants before any interventions. This one-sided, randomized clinical trial (IRCT20230212057391N1) was conducted in Taleghani Burn Hospital in Ahvaz, Iran in 2023.

It was with a prospective research design conducted on burn patients with scars lasting for one year since their diagnosis. These cases had referred to health care facilities and shown their willingness to cooperate.

Participants

Of note, the burn patients were included in this study based on the presence of HTS and keloids. In this respect, the inclusion criteria were the patients with HTS and keloids in need of injections. On the other hand, the exclusion criteria focused on pregnant women and lactating mothers, the patients suffering from mental health problems, those with inability to write or read in Persian, the incarcerated ones, and the individuals expressing their reluctance to contribute to the study. In the beginning, informed written consent was obtained from the burn patients, and the research objectives as well as the desired procedures and parameters were fully explained to them. This study was to compare the effect of MMC injection on HTS and keloids in burn patients, and then compare it with intralesional steroid, triamcinolone acetonide (TAC), injection in

[Downloaded from wjps.ir on 2026-11-25]

[DOI: 10.61882/wjps.14.3.70]

the same cases with regard to scar size reduction and recurrence rate.

Randomization and Intervention

In total, 90 burn patients, randomized into two groups (each one consisting of 45 cases), namely, Group A and Group B, receiving MMC (0.4 mg/dl) and TAC (0.4 mg/dl) injections, respectively. The intralesional injection sites were then determined. After that, MMC and TAC were injected into the scars of the selected patients within a six-month interval.

Outcome Assessment

Subsequently, the burn patients were evaluated based on a six-month interval in terms of both injection sites in respect of scar size reduction, and changes in scar color and vascularity, tissue flexibility, and width with reference to the Vancouver Scar Scale (VSS) scores and localized itching. After six months, the changes were compared with the conditions at the time of injections, and patient satisfaction with scar complications were objectively questioned and evaluated. The burn patients were further compared in relation to the scar tissue and site along with response rates to MMC and TAC injections.

RESULTS

Participant Characteristics

Out of 90 burn patients in need of injections, Table 1 shows the demographic characteristics. With regard to the burn site, 14 patients had burns on their forearms, and 24, 4, 12, 11, 20, and 5 cases had burns on their hands, knees, legs, thighs, arms, and calves, respectively. Additionally, the most frequent burns were related to those on the hands (26.7%), and the least ones had occurred on their legs (5.6%).

Table 1: Demographic characteristics of burn patients

Variable		Frequency	Percent
Sex	Male	40	44.4
	Female	50	55.6
Age(yr)	Mean±SD	Minimum	Maximum
	36.68±3.72	30	45

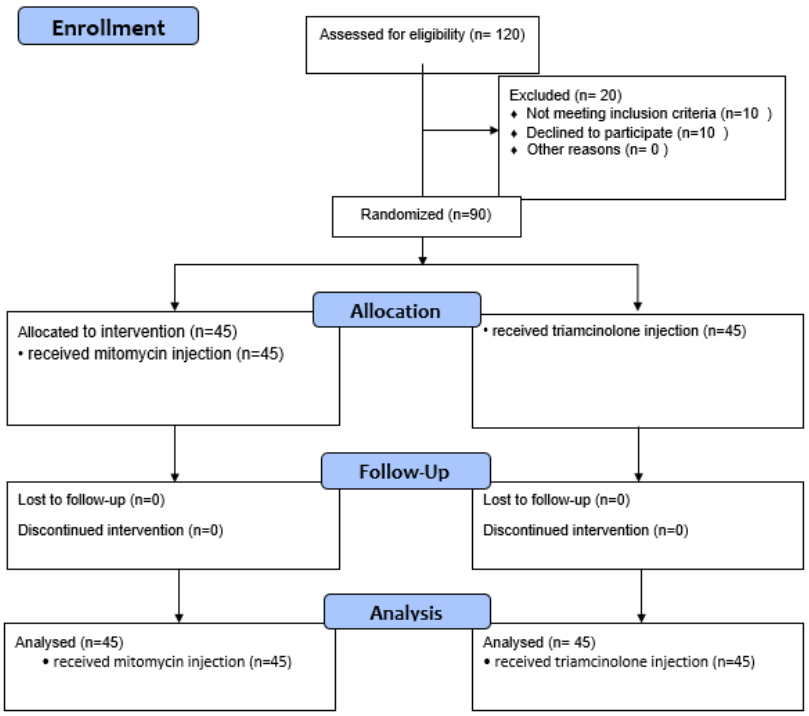

Figure 1: The Flowchart of the study

[Downloaded from wjps.ir on 2026-11-25]

[DOI: 10.61882/wjps.14.3.70]

Changes in scar size before and after intervention

Examining the scar size in the burn patients at the pre- and post-intervention stages also revealed that the average size before the intervention was equal to 15.71±5.13 and that was 4.18±2.70 following its completion. Utilizing the independent-samples t-test, a statistically significant difference was thus found between the scar size before and after the intervention (P<0.001) (Figure 2, Table 2).

Comparison between treatment groups

Comparing the scar size in the burn patients based on the MMC and TAC injections at the pre- and post-intervention stages, using one-way analysis of variance (ANOVA), the scar size had shrunk after the MMC injection higher than TAC. The average scar size during the TAC and MMC injections before the intervention was respectively 15.48±4.03 and 15.93±6.08, so there was no significant difference between both study groups. However, after the intervention, the average scar size following TAC and MMC injections was 6.22±2.23 and that was 2.15±1.14, in that order, so a significant difference was established between these two groups (P<0.05). Accordingly, scar size reduction upon MMC application was more than that in TAC, representing that the effect of MMC injection was more than TAC in burn repair (Figure 3, Table 3).

VSS Assessment

The VSS scores at the pre- and post-intervention stages in the burn patients were correspondingly compared via one-way ANOVA. In this way, the VSS mean score before and after the intervention was significantly different, to the extent that the mean score for TAC was higher than that of MMC, while the values before and after the intervention had a significant difference (Figure 4, Table 4).

Outcomes

The images presented in Figure 5 and Figure 6 demonstrate the efficacy of MMC injection in the treatment of hypertrophic scars and keloids. The positive outcomes observed in both cases suggest that this treatment modality holds promise for individuals seeking to alleviate the cosmetic and functional concerns associated with these types of skin conditions.

Table 2: Scar size in burn patients at pre- and post-intervention stages

Variable	Treatment stage	Mean	SD	*P*-value
Scar size	Before treatment	15.71	5.13	<0.001
	After treatment	4.18	2.70	

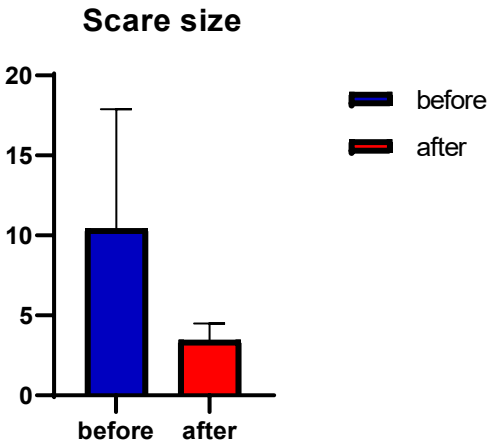

Figure 2: Comparison of scar size before and after the intervention

[Downloaded from wjps.ir on 2026-11-25]

[DOI: 10.61882/wjps.14.3.70]

Table 3: Scar size in burn patients at pre- and post-intervention stages

Variable	Treatment stage	Mean	SD	*P*-value
Scar size	Mitomycin before intervention	15.48	4.03	<0.001
	Triamcinolone after intervention	15.93	6.08	
	Mitomycin after intervention	6.22	2.23	
	Mitomycin before intervention	2.15	1.14	

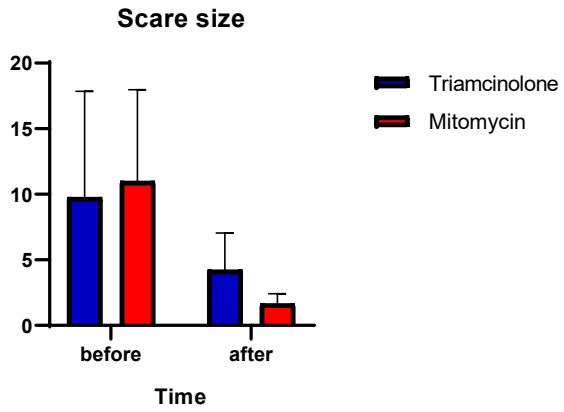

Figure 3: Comparison of scar size in mitomycin and keloids before and after the intervention

Table 4: Scar size in burn patients at pre- and post-intervention stages

Variable	Treatment stage	Mean	SD	*P*-value
Scar size	Mitomycin before intervention	13	2.41	<0.001
	Triamcilonone after intervention	12.13	2.36	
	Mitomycin after intervention	4.86	1.16	
	Mitomycin before intervention	4.78	0.67	

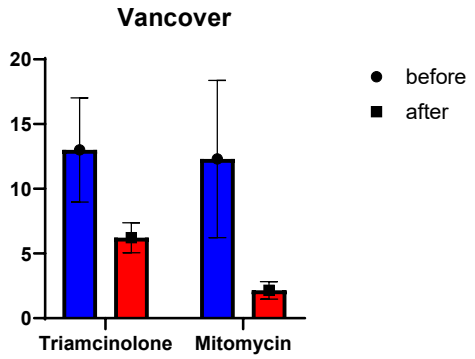

Figure 4: Comparison of VSS scores for MMC and TA at pre- and post-intervention stages



Figure 5: Hypertrophic scar on the left shoulder in a 33-year-old man (A) Before the initiation of treatment; (B) at 12 weeks after mitomycin C injection

[Downloaded from wjps.ir on 2026-11-25]

[DOI: 10.61882/wjps.14.3.70]



Figure 6: Keloid on the chest wall in a 23-year-old weman (A) Before the initiation of treatment; (B) at 12 weeks after mitomycin C injection

DISCUSSION

HTS and Keloids, as heightened inflammatory responses, have turned out to be big challenges faced by physicians when treating burn patients. The cases susceptible to developing such scars are typically under 30 years old and have dark skin.

Notably, the skin on the chest, shoulders, arms, earlobes, and cheeks are prone to HTS and keloids than other body areas. These scars can be much larger than the original wounds, and even affect any part of the body. Although HTS and keloids are not harmful to health, the main concern is associated with cosmetic skin problems in the affected areas.

So far, a vast number of therapeutic methods have been tested to successfully treat such scars [7], including occlusive dressings, intralesional corticosteroid injection, cryosurgery, MMC use, surgical excision, radiation therapy, laser treatment, interferon alfa-2b, 5-FU, doxorubicin, and bleomycin injections, as well as verapamil prescription, retinoic acid, imiquimod topical application, tamoxifen, tacrolimus, botulinum toxin, and over-the-counter (OTC) treatments [8].

Surgery can also lead to immediate correction in appearance and cosmetic outcomes, but the recurrence rate following it alone is relatively high, from 45 to 100%. The incidence rate has been further reported between 4 and 16% in the black population. In the present study, most of the burn patients were in the age range of 36.68±3.72, whereas the bulk of those recruited in Sengupta et al [9] were in the age group of 10 to 30. Moreover, most of the participants (55.6%) in the present study were female, which was consistent with those reported in Gupta [10], Chi [11], and Fruth [12] studies. Yielding good results in the treatment of HTS and keloids seems to be exceedingly difficult, to the extent that the recurrence rate following excision is 50-60%. All the treatment methods mentioned above have up to now met limited success. A great deal of such interventions has also significantly failed. No matter the methods of surgery, the dermis is much more damaged, thereby proliferating fibroblasts, producing excessive collagen, and then resulting in the formation of scars. Some procedures are also aggressive, while others seem to minimize the lesions with no trouble. The biological nature of HTS and keloids is poorly understood, but there is no doubt that fibroblasts are to blame. Such scars are associated with significant pain, itching, and disfigurement. As well, postoperative recurrence remains a therapeutic challenge [13].

In this line, the intralesional injection of corticosteroid, such as TAC, has been recognized as one of the first-line treatments for HTS and keloids, as they are well tolerated by burn patients. Corticosteroids can also moderate collagen synthesis and prevent the rapid growth of fibroblasts within the given scars. In addition, they lead to vasoconstriction in HTS and keloids, and control local inflammation. Nevertheless, the response rate of TAC-based treatment might significantly differ with a high recurrence rate. TAC monotherapy may further cause hypopigmentation, mixed pigmentation, fat atrophy, telangiectasias, necrosis, ulceration, and Cushingoid. Besides, there is much concern regarding the frequent use of high-dose corticosteroids in patients with large and multiple HTS and keloids [14, 15].

In this respect, MMC has been introduced as an antibiotic produced by *Streptomyces caespitosus* that helps alkylate and bind DNA, thereby inhibiting its synthesis in neoplastic cells. In high doses, MMC can even hinder ribonucleic acid (RNA) and protein synthesis. Furthermore, it blocks vascularization during wound healing. MMC further prompts apoptosis in fibroblasts, and diminishes induced transforming growth factor-beta (TGF-β) production, whose isoforms take the lead in wound healing and fibrosis. Considering its ability to inhibit fibroblast proliferation and activity, MMC

[Downloaded from wjps.ir on 2026-11-25]

[DOI: 10.61882/wjps.14.3.70]

can additionally affect fibroblasts without disturbing re-epithelialization.

The study results here indicated that the scar size reduced much more after MMC injection than TAC; as a result, MCC was more effective than TAC, which was statistically significant. Moreover, the VSS mean scores at the pre- and post-intervention stages showed a significant difference, in a way that this value for TAC was higher than that of MCC. Numerous studies had already investigated the effect of MCC on HTS and keloids. For example, Seo et al [16] had treated nine patients with HTS and keloids via MMC topical (1 mg/ml) for three minutes after surgery. As well, intralesional MMC (1 mg/ml) had been prescribed to shed light on its effect on regression in such scars in two patients. Finally, the VSS scores, patient satisfaction, and side effects had been evaluated after six months, suggesting that six out of nine cases had reached excellent results in terms of size change, and three patients had faced a local recurrence.

Compared with the conditions before the MMC injection, the scars had been soft with a slight reduction in their size, but there had been some erythema, pain, and itching, which had improved following intralesional steroid injection. The results reported by Mandour et al [17], comparing topical and intralesional injections of MMC in the treatment of ear keloids, had further revealed that the post-intervention VSS scores had respectively dropped from 10.63 and 11.0 to 1.38 and 3.0 in the topical and intralesional groups, demonstrating a significant fall. However, more improvement and satisfaction had been observed in the group receiving local MMC.

In comparison with this investigation, the intralesional injection of MMC after the intervention moderated the VSS scores in the present study. In Sanders et al [18], MMC (0.4 mg/ml) had been injected for five minutes before wound closure in keloids on different parts of the head and neck of 15 patients. Then, a postoperative TAC regimen (40 mg/ml) had been started one month later for six months. Accordingly, the scar size had a complete reduction in eight patients after two months of injection, but six patients had experienced a relative reduction in this respect.

One patient had no scar size reduction. Sengupta et al [9], comparing the effectiveness of topical MMC (1 mg/ml) and intralesional TAC (40 mg/ml) injections in lowering the rate of keloid recurrence, six months after surgery, had established no significant difference in the MMC and TAC groups, so five and six cases of recurrence had been reported after MMC and TAC use, respectively. According to Stewart et al [19], recurrence had not been observed in nine out of 10 patients after eight months of follow-up in the wake of the postoperative topical MMC injection with the concentration of 0.4 mg/ml for four minutes. Somewhere else, 20 patients had undergone surgery, and then treated with MMC for five minutes, in which all patients had expressed their satisfaction after 14 months of follow-up and two cases had reported the complete removal of HTS and keloids, even though Sanders et al [18] had established that the topical application of MMC to excised scars had left no difference in recurrence rates. Besides, Simman et al [20], examining the effect of exposure to MMC (0.1 mg/ml) for five minutes on keloid fibroblasts in vitro, had concluded a decline in fibroblast density and DNA synthesis three weeks later. Sewall et al [21] had also evaluated the effect of topical MMC on full-thickness skin wound contraction in mice, and found that the contraction speed had been significantly slower in the treated group than the controls. Additionally, the intervention group had encountered a significantly larger wound area after one month, while the wound area in the controls had shrunk almost nine times faster. In this vein, Talmi et al [22] had further evaluated the effect of MMC application as an adjuvant treatment after keloid removal, and observed that all patients had felt satisfied with the results, but complete removal had been merely evident in two cases. These results were considered positive because simple excision and wound closure had been accompanied by the recurrence rate of 45-100%.

CONCLUSION

With reference to the study results and previous research, the application of MMC can be effective in the treatment of HTS and keloids even though its effect in terms of healing and recurrence rate has been thus far different due to discrepancies in the type of injection (viz., topical or intralesional), MMC application before or after surgery, MMC dose, injection duration, sample size, scar site, scar size, follow-ups, and outcome evaluations. The limitations facing the present study included

[Downloaded from wjps.ir on 2026-11-25]

[DOI: 10.61882/wjps.14.3.70]

small sample size, no investigation of the effect of MMC with regard to the lesion site, and no focus on recurrence rate. Both MMC and TAC were generally considered as effective methods for HTS and keloid management. In spite of this, the VSS scores and the scar size denoted that MMC was much more effective in the treatment of such scars than TAC. Further studies are thus needed to reflect on the effects of MMC use and compare it with other treatment methods for HTS and keloids.

FUNDING STATEMENT

This study is a part of Plastic Surgery Subspecialty Fellowship thesis by Jafar Jafarzadeh, which was approved and financially supported by a grant (U-01210) from Research Affairs, Ahvaz Jundishapur University of Medical Sciences, Ahvaz, Iran.

ACKNOWLEDGMENTS

We would also like to show our gratitude to the Clinical Research Development Unit, Golestan Hospital, Ahvaz Jundishapur University of Medical Sciences, Ahvaz, Iran for sharing their pearls of wisdom with us during the course of this research.

CONFLICT OF INTEREST

The authors declare that there is no conflict of interests.

REFERENCES

1. Zhang W, Li X, Li X. Efficacy and Safety of Verapamil versus Triamcinolone Acetonide in Treating Keloids and Hypertrophic Scars: A Systematic Review and Meta-Analysis. *Aesthetic Plast Surg.* 2023;**47**:473-482. doi: 10.1007/s00266-022-03229-3.
2. Ung CY, Warwick A, Onoufriadis A, Barker JN, Parsons M, McGrath JA, Shaw TJ, Dand N. Comorbidities of Keloid and Hypertrophic Scars Among Participants in UK Biobank. *JAMA Dermatol.* 2023; **159**:172-181. doi: 10.1001/jamadermatol.2022. 5607.
3. Frech FS, Hernandez L, Urbonas R, Zaken GA, Dreyfuss I, Nouri K. Hypertrophic Scars and Keloids: Advances in Treatment and Review of Established Therapies. *Am J Clin Dermatol* 2023; **24**:225-245. doi: 10.1007/s40257-022-00744-6.
4. Sengupta A, Das A, Ghosh D, Dhara S, Ghosh S, Sengupta A, Bhattacharya S. The efficacy of local application of mitomycin c in reducing recurrence rate of keloid after surgery. *Bengal J Otolaryngol Head Neck Surg* 2016;**24**:117-21. doi.org/10.47210/bjohns.2016.v24i3.88
5. Gupta M, Narang T. Role of mitomycin C in reducing keloid recurrence: patient series and literature review. *J Laryngol Otol* 2011;**125**:297-300. doi: 10.1017/S0022215110002045.
6. Chi SG, Kim JY, Lee WJ, Lee SJ, Kim DW, Sohn MY, Kim GW, Kim MB, Kim BS. Ear keloids as a primary candidate for the application of mitomycin C after shave excision: in vivo and in vitro study. *Dermatol Surg* 2011; **37**:168-75. doi: 10.1111/j.1524-4725.2010.01846. x.
7. Fruth K, Gouveris H, Kuelkens C, Mann WJ. Radiofrequency tissue volume reduction for treatment of auricle keloids. *Laryngoscope* 2011;**121**:1233-6. doi: 10.1002/lary.21782.
8. Trace AP, Enos CW, Mantel A, Harvey VM. Keloids and Hypertrophic Scars: A Spectrum of Clinical Challenges. *Am J Clin Dermatol* 2016;**17**:201-23. doi: 10.1007/s40257-016-0175-7.
9. Liu XG, Zhang D. Evaluation of Efficacy of Corticosteroid and Corticosteroid Combined with Botulinum Toxin Type A in the Treatment of Keloid and Hypertrophic Scars: A Meta-Analysis. *Aesthetic Plast Surg* 2021;**45**:3037-3044. doi: 10.1007/s00266-021-02426-w.
10. Roques C, Téot L. The use of corticosteroids to treat keloids: a review. *Int J Low Extrem Wounds* 2008; **7**:137-45. doi: 10.1177/1534734608320786.
11. Seo SH, Sung HW. Treatment of keloids and hypertrophic scars using topical and intralesional mitomycin C. *J Eur Acad Dermatol Venereol* 2012; **26**:634-8. doi: 10.1111/j.1468-3083.2011.04140. x.
12. Mandour Y, Bake H, Mofty E, Ramadan E, Gomaa M, Akl E, Elrefae A. Topical versus interlesional mitomycin C in auricular keloids. *Acta Otorrinolaringol Esp (Engl Ed)* 2021; **72**:280-287. doi: 10.1016/j.otoeng.2020.06.006.
13. Sanders KW, Gage-White L, Stucker FJ. Topical mitomycin C in the prevention of keloid scar recurrence. *Arch Facial Plast Surg* 2005; **7**:172-5. doi: 10.1001/archfaci.7.3.172.
14. Simman R, Alani H, Williams F. Effect of mitomycin C on keloid fibroblasts: an in vitro study. *Ann Plast Surg* 2003;**50**:71-6. doi: 10.1097/00000637-200301000-00012.
15. Talmi YP, Orenstein A, Wolf M, Kronenberg J. Use of mitomycin C for treatment of keloid: a preliminary report. *Otolaryngol Head Neck Surg* 2005;**132**:598-601. doi: 10.1016/j.otohns.2004.09.060.
16. Bao Y, Xu S, Pan Z, Deng J, Li X, Pan F, et al. Comparative efficacy and safety of common therapies in keloids and hypertrophic scars: a

[Downloaded from wjps.ir on 2026-11-25]

[DOI: 10.61882/wjps.14.3.70]

systematic review and meta-analysis. *Aesthet Plast Surg*. 2020;**44**(1):207-18.
17. Grabowski G, Pacana MJ, Chen E. Keloid and hypertrophic scar formation, prevention, and management: standard review of abnormal scarring in orthopaedic surgery. *J Am Acad Orthop Surg*. 2020;**28**(10):e408-e14.
18. Knowles A, Glass DA. Keloids and hypertrophic scars. *Dermatol Clin*. 2023;**41**(3):509-17.
19. Zheng M, Hwang S, Snyder T, Aquilina J, Proni G, Paz MM, et al. Synthesis of mitomycin C and decarbamoylmitomycin C N6 deoxyadenosine-adducts. *Bioorg Chem*. 2019;92:103280.
20. Naik P. Novel targets and therapies for keloid. *Clin Exp Dermatol*. 2022;**47**(3):507-15.
21. Elazhary EA, Abd Al-Salam F, Abd El-Hafiz HS, Maghraby HM. Updates on keloid scar pathogenesis, assessment and treatment modalities. *J Recent Adv Med*. 2022;**3**(1):75-86.
22. Zamanian A, Nokandeh M, Behrangi E, Fazel Z, Azizian Z. Comparing efficacy and tolerability of triamcinolone and verapamil in treatment of hypertrophic scars and keloids. *J Skin Stem Cell*. 2017;**4**(3-4):e69390.
23. Ung CY, Warwick A, Onoufriadis A, Barker JN, Parsons M, McGrath JA, Shaw TJ, Dand N. Comorbidities of Keloid and Hypertrophic Scars Among Participants in UK Biobank. *JAMA Dermatol*. 2023; **159**(2):172-181.
24. Sengupta A, Das A, Ghosh D, Dhara S, Ghosh S, Sengupta A, Bhattacharya S. The efficacy of local application of mitomycin c in reducing recurrence rate of keloid after surgery. *Bengal J Otolaryngol Head Neck Surg*. 2016;**24**(3):117-21.
25. Gupta M, Narang T. Role of mitomycin C in reducing keloid recurrence: patient series and literature review. *J Laryngol Otol*. 2011;**125**(3):297-300.
26. Chi SG, Kim JY, Lee WJ, Lee SJ, Kim DW, Sohn MY, Kim GW, Kim MB, Kim BS. Ear keloids as a primary candidate for the application of mitomycin C after shave excision: in vivo and in vitro study. *Dermatol Surg*. 2011; **37**(2):168-75.
27. Fruth K, Gouveris H, Kuelkens C, Mann WJ. Radiofrequency tissue volume reduction for treatment of auricle keloids. *Laryngoscope*. 2011;**121**(6):1233-6.
28. Trace AP, Enos CW, Mantel A, Harvey VM. Keloids and Hypertrophic Scars: A Spectrum of Clinical Challenges. *Am J Clin Dermatol*. 2016;**17**(3):201-23.
29. Roques C, Téot L. The use of corticosteroids to treat keloids: a review. *Int J Low Extrem Wounds*. 2008; **7**(3):137-45.
30. Liu XG, Zhang D. Evaluation of Efficacy of Corticosteroid and Corticosteroid Combined with Botulinum Toxin Type A in the Treatment of Keloid and Hypertrophic Scars: A Meta-Analysis. *Aesthetic Plast Surg*. 2021;**45**(6):3037-3044.
31. Seo SH, Sung HW. Treatment of keloids and hypertrophic scars using topical and intralesional mitomycin C. *J Eur Acad Dermatol Venereol*. 2012; **26**(5):634-8.
32. Mandour Y, Bake H, Mofty E, Ramadan E, Gomaa M, Akl E, Elrefae A. Topical versus interlesional mitomycin C in auricular keloids. *Acta Otorrinolaringol Esp (Engl Ed)*. 2021; **72**(5):280-287.
33. Sanders KW, Gage-White L, Stucker FJ. Topical mitomycin C in the prevention of keloid scar recurrence. *Arch Facial Plast Surg*. 2005; **7**(3):172-5.
34. Stewart IV CE, Kim JY. Application of mitomycin-C for head and neck keloids. Otolaryngol Head Neck Surg. 2006;**135**(6):946-50.
35. Simman R, Alani H, Williams F. Effect of mitomycin C on keloid fibroblasts: an in vitro study. *Ann Plast Surg* 2003;**50**:71-6. doi: 10.1097/00000637-200301000-00012.
36. Sewall GK, Robertson KM, Connor NP, Heisey DM, Hartig GK. Effect of topical mitomycin on skin wound contraction. Archives of facial plastic surgery. 2003;5(1):59-62.
37. Talmi YP, Orenstein A, Wolf M, Kronenberg J. Use of mitomycin C for treatment of keloid: a preliminary report. *Otolaryngol Head Neck Surg* 2005;**132**:598-601. doi: 10.1016/j.otohns.2004.09.060.

[Downloaded from wjps.ir on 2026-11-25]

[DOI: 10.61882/wjps.14.3.70]