Case Report

Surgical Management of Gynecomastia in Asian Men - Clinical Experience and Considerations for Different Patient Types

Ivan Boon Kwang Puah [1*]

1. Amaris B. Clinic, Singapore, Singapore.

ABSTRACT

Gynecomastia, the excess growth of glandular breast tissue in males, is a common condition associated with hormonal imbalance or the use of certain drugs. Although medically benign, persistent gynecomastia often causes psychological distress and adversely affects quality of life. Published literature on the evaluation and management of patients seeking surgical treatment for gynecomastia is predominantly from Western populations. Here, we present insights from our practice in a multi-ethnic Asian population, with >550 cases treated at Amaris B. Clinic, Singapore from 2018–2023. We illustrate these insights and principles with a representative selection of 6 patient cases. We discuss specific considerations for optimizing the consultation process and outcomes in Asian patients, with reference to profiles commonly seen in our local setting. These were: adult males, the most encountered patient profile who are typically overweight/obese; young (adolescent) males, typically overweight, had a history of recent significant weight loss, or lean and experiencing gynecomastia due to puberty-related hormonal changes; males with drug-induced gynecomastia, typically athletes/bodybuilders. Our experience highlights several important considerations, including management of the consultation process, the range of patient expectations, and addressing surgical aspects of management to achieve the desired aesthetic outcomes.

KEYWORDS
Gynecomastia; Male breast surgical treatment; Patient categorization; Surgical expectations; Treatment outcomes

Please cite this paper as:
Puah IBK. Surgical Management of Gynecomastia in Asian Men - Clinical Experience and Considerations for Different Patient Types. World J Plast Surg. 2025;14(3):101-107.
doi: 10.61882/wjps.14.3.101

***Corresponding Author:**

Ivan Boon Kwang Puah

Amaris B. Clinic, Singapore, Singapore

Email: customer@amaris-b.com

Received: 8/4/2025
Accepted: 11/17/2025

INTRODUCTION

Gynecomastia, the benign proliferation of glandular breast tissue in males, is a common condition with various causes, including hormonal imbalances and the use of specific drugs [1]. Although often asymptomatic, intervention may be warranted when it is associated with physical discomfort and psychological distress, adversely affecting an individual's body image and self-confidence and ultimately leading to

[Downloaded from wjps.ir on 2026-11-25]

[DOI: 10.61882/wjps.14.3.101]

a reduced quality of life (QoL) [2]. The key objectives for gynecomastia surgery are to relieve physical symptoms and improve the visual appearance of the chest by emphasizing a masculine contour. To some individuals, additional aspects such as the appearance of minimal body fat and good musculature definition are especially important. Most patients experience substantial improvements in their overall well-being and reduced psychological distress once these issues are addressed.

With Singapore's multi-ethnic Asian-majority population, most of the patients seeking surgical gynecomastia correction at our clinic are Asian. In contrast, most of the published literature on gynecomastia management relates to Western patient populations. With 15 years of experience in optimizing aesthetic outcomes for a diverse population of Asian patients seeking surgical gynecomastia correction, we recognize key differences between Asian and Western patients that we find to be important for effective and personalized management. Here, we highlight these differences and their implications for gynecomastia surgical management and present insights from our practice in a multi-ethnic Asian population, with over 550 cases treated at our clinic between 2018 and 2023. We illustrate these insights and principles with a representative selection of 6 patient cases to present the nuanced approach we adopted to achieve successful and aesthetically pleasing outcomes.

General considerations for Asian patients

Asians, which refers to individuals from the East, South East, and South Asia or the Indian subcontinent, exhibit diverse skin phototypes ranging from Fitzpatrick type III to V in East Asian populations to type IV and V in individuals from South Asia and the Indian subcontinent [3, 4]. Those with skin types IV to V are known to be more susceptible to prominent scarring [5]. Additionally, Asian individuals generally have a thicker and more fibrous dermal layer compared with Caucasian individuals, who generally exhibit less thickness in equivalently pigmented skin [6]. Practitioners have noted that this increased collagen density, even in lightly pigmented Asian individuals, may contribute to an intensified fibroblastic response during wound healing [7, 8]. This may manifest as proneness to hypertrophic scarring and prolonged erythema during scar maturation, leading to scars that are raised, thick, and/or discolored. The emphasis on minimal scarring is particularly important in regions like Singapore, where the hot and humid climate requires light clothing, which offers less concealment, to accommodate the warm weather. As issues with scarring and hyperpigmentation can be aesthetically concerning, optimization of surgical techniques and post-surgical management for Asian patients with gynecomastia is beneficial.

Our general surgical approach involves a single incision along the inferior-lateral border of the areola. This not only provides enhanced access to the bulk of the glandular tissue typically located lateral to the nipple but also minimizes the visibility of post-surgical scars. In our experience, Asian patients tend to have glandular tissue that is more fibrous and often extends into the lateral and superior-lateral areolar regions, necessitating thorough exploration of these areas. Following gland excision, breast fat and lateral chest fat pads are removed by liposuction. Customized fine liposuction cannulas and small-diameter suction tubing are employed, allowing the use of smaller incisions (<4mm). Our technique also involves undermining of the subdermal layers, achieved by maneuvering liposuction cannulas in precise directions and depths beneath the skin, to further enhance skin tightening and produce a better post-surgical appearance.

We also found that the increased vascularity of the fibrous glandular tissues in Asian patients requires careful hemostasis to reduce the risk of post-surgical hematoma. Our protocol generally allows surgical drains to be omitted without increasing the risk of hematoma. This is advantageous as it minimizes the risk of scarring and infection, and yields a more aesthetically pleasing result. Post-surgery, a pressure bandage and compression garment are applied to support the healing process and optimize the contour of the treated area.

CASE PRESENTATION

Cases 1 and 2: Adult males

At our clinic, the majority of patients seeking surgical correction for gynecomastia are adult males suffered from the condition since adolescence. They often report a history of body image concerns related to overweight or obesity. In most cases,

[Downloaded from wjps.ir on 2026-11-25]

[DOI: 10.61882/wjps.14.3.101]

patients have excess fat in the chest and abdominal area as well as glandular tissue hypertrophy and may have related issues such as loose skin. This requires a surgical approach that not only reduces breast tissue but also addresses skin laxity through tightening procedures. Their aesthetic expectations are generally moderate, and they usually seek a realistic and sustainable improvement rather than a drastic transformation.

This patient profile is exemplified by two cases: a 28-year-old Chinese male (Figure 1A) and a 21-year-old Indian male (Figure 1B), both of whom had been overweight since childhood and reported no reduction in breast enlargement despite losing weight. Both patients were diagnosed with grade 4 gynecomastia, as determined by the American Society of Plastic Surgeons (ASPS) gynecomastia scale. The ASPS scale is an adaptation of the McKinney and Simon, Hoffman, and Kohn scales [9]. As is typical for this patient profile, skin laxity was present (Figure 1A – mild; Figure 1B – moderate). For both patients, bilateral breast gland excision and liposuction were performed to remove excess breast and lateral chest wall fat. Additionally, undermining of the subdermal skin layers was performed to enhance tissue tightening and reduce skin laxity. Figures 1C and 1D show the post-operative results of the patients. At the 3-month follow-up, both patients showed no complications, emphasizing the effectiveness of our tailored approach. They expressed high satisfaction regarding the aesthetic results of the procedure, rating it a 7 out of 7.

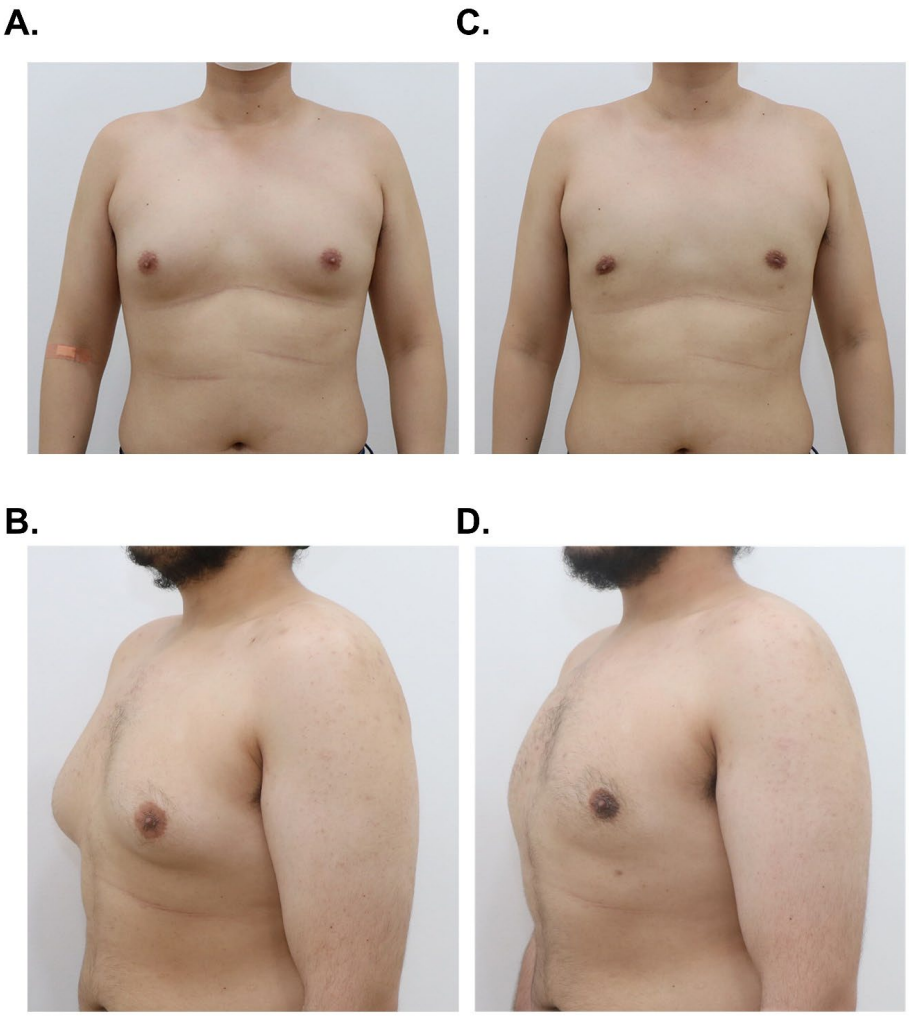

Figure 1: Outcomes of gynecomastia surgery in adult patients

Case 1: 28-year-old Chinese male, BMI 23.5; ASPS grade 4 gynecomastia. Case 2: 21-year-old Indian male, BMI 27.8; ASPS grade 4 gynecomastia. (A) Pre-operative frontal view of Case 1; (B) pre-operative oblique view of Case 2. (C) Post-operative frontal view of Case 1 (D) post-operative oblique view of Case 2. The post-operative images illustrate a natural-looking aesthetic result, with a markedly improved chest contour, minimal skin laxity, and no visible scarring

[Downloaded from wjps.ir on 2026-11-25]

[DOI: 10.61882/wjps.14.3.101]

Cases 3 and 4: Younger (adolescent) males

Young males (adolescents) represent another major group of patients seeking consultation in our clinic. Patients within this group can generally be categorized into two types: 1) those who are overweight or have a history of recent significant weight loss and 2) lean patients experiencing gynecomastia due to puberty-related hormonal changes. Given their age and their typical social environments (e.g., school, or military service, which is compulsory in Singapore), these patients may experience emotional distress, teasing, or bullying by peers. These psychosocial challenges are often exacerbated by peer comparisons, leading to complex body image-related issues. Patients frequently harbor expectations that their condition will spontaneously resolve with weight loss or after adolescence, leading to further disappointment and distress if this does not occur. Recognizing their heightened concerns about their appearance, for this group of patients, we focus on removing enlarged breast tissue while enhancing chest shape and contour through precise liposuction sculpting. As done for other groups, the risk of visible scarring is minimized through strategically placed incisions and use of smaller liposuction cannulas and tubing. This patient profile is exemplified by two cases: a 17-year-old Chinese male (ASPS grade 2; Figure 2A) and an 18-year-old Chinese male (ASPS grade 2; Figure 2B), both of whom had a history of bilateral breast enlargement since the ages of 13 and 12, respectively. Both patients underwent bilateral breast

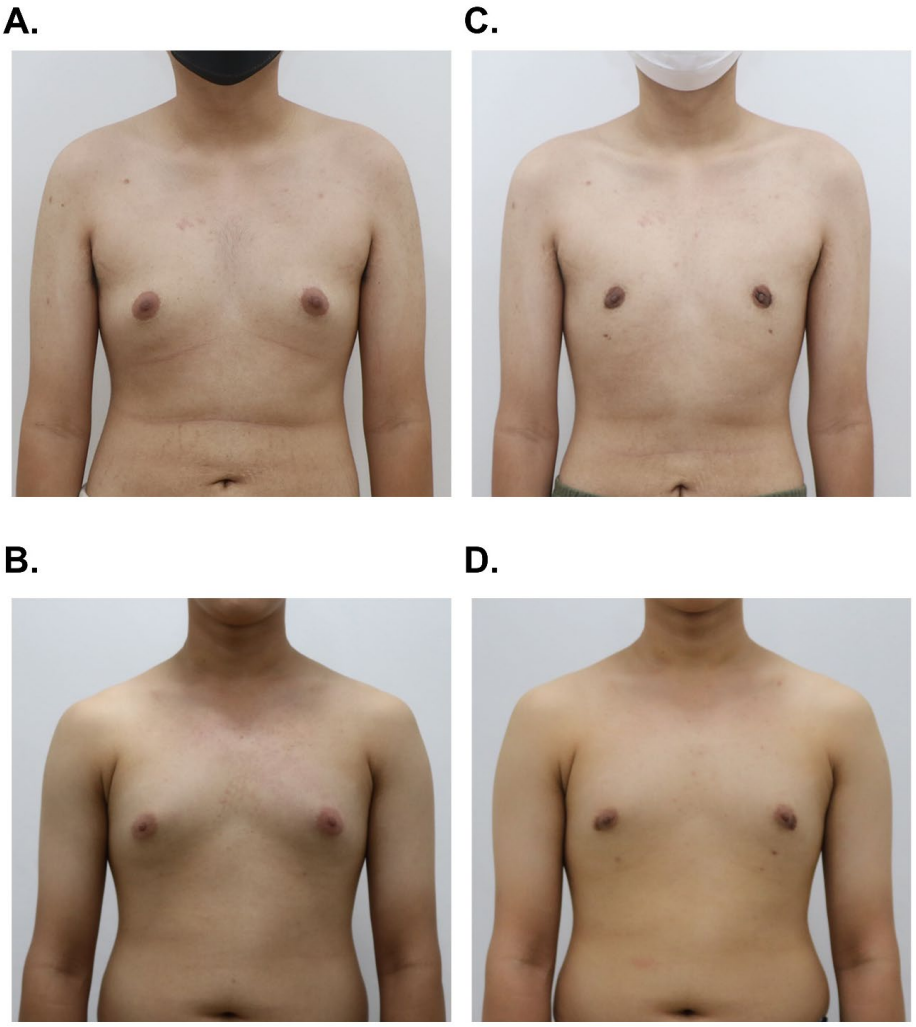

Figure 2: Outcomes of gynecomastia surgery in younger (adolescent) patients

Case 3: 17-year-old Chinese male, BMI 22.7; ASPS grade 2 gynecomastia. Case 4: 18-year-old Chinese male, BMI 24.4; ASPS grade 2 gynecomastia. (A) Pre-operative frontal view of Case 3; (B) pre-operative frontal view of Case 4. (C) Post-operative frontal view of Case 3 (D) post-operative frontal view of Case 4. The post-operative images illustrate the reduction in breast tissue with a natural-looking aesthetic result and a markedly improved chest contour with minimal to no visible scarring

[Downloaded from wjps.ir on 2026-11-25]

[DOI: 10.61882/wjps.14.3.101]

gland excision and liposuction for debulking and chest contouring. Figures 2C and 2D show the post-operative frontal view of the patients. At the 3-month follow-up, Case 3 exhibited no complications, while Case 4 had mild keloidal scar formation at the edges of both areolae, where the surgical incisions were made, although these were not easily noticeable. Both patients reported high satisfaction with the aesthetic outcomes of the surgery, rating it a 7 out of 7.

Cases 5 and 6: Males with drug-induced gynecomastia

Another group frequently seen in our practice is men with drug-induced gynecomastia, often bodybuilders or athletic individuals. These patients are typically lean and muscular, with minimal fat in the chest area. They may report previous/current use of anabolic steroids or certain other medications. Surgical correction is sought to address breast enlargement and other symptoms that do not resolve after drug discontinuation. In these cases, breast tissue tends to be more fibrotic as well as enlarged, often extending into the lateral or superior-lateral aspects of the peri-areolar region. This necessitates careful surgical exploration to ensure complete excision of the glands. Moreover, meticulous attention to hemostasis is important due to the increased vascularity of the glands and their proximity to underlying muscle layers, which may bleed easily given the minimal fatty tissue present.
Many of these patients are highly conscious of

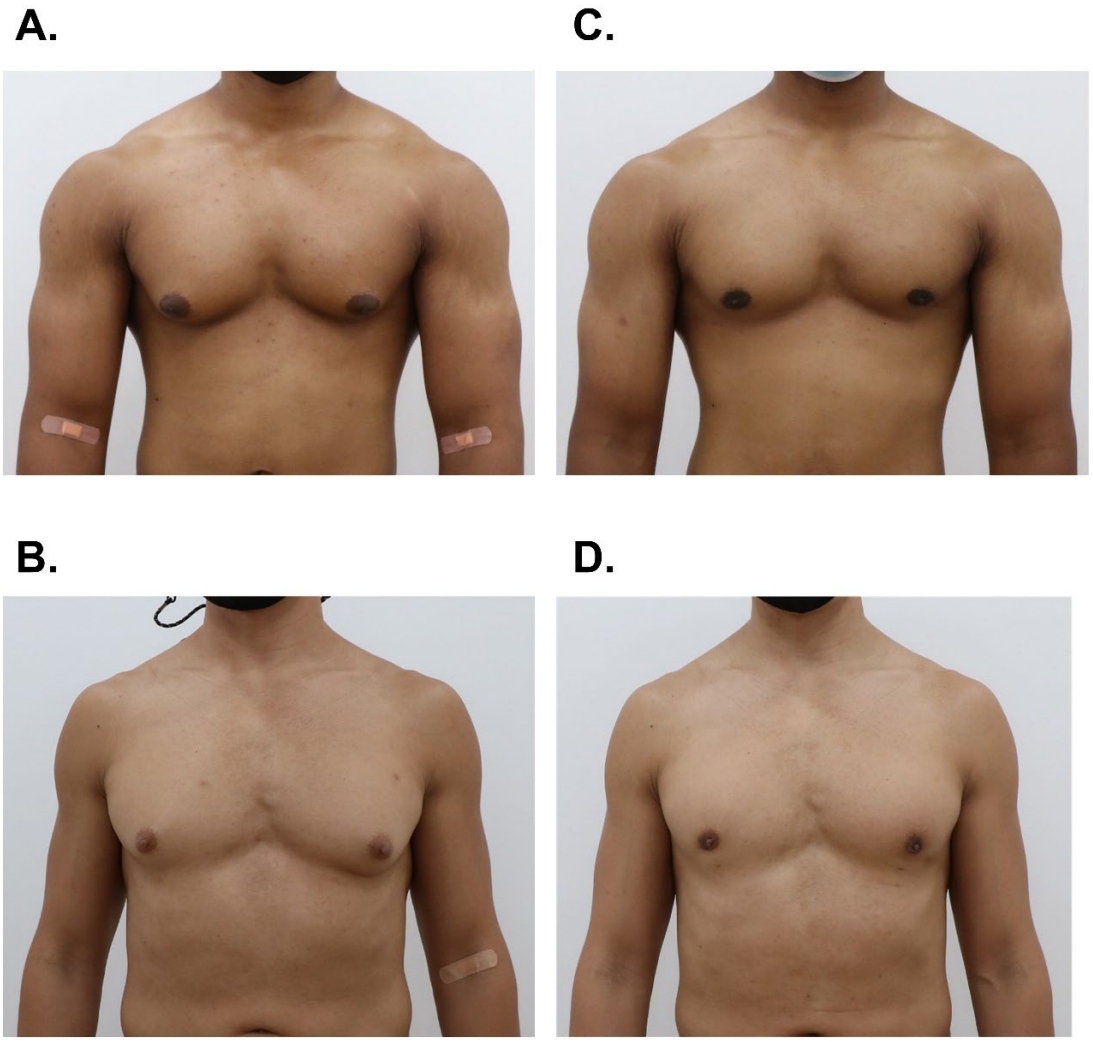

Figure 3: Outcomes of gynecomastia surgery in patients with drug-induced gynecomastia

Case 5: 22-year-old Malay male, BMI 30.7; ASPS grade 2 gynecomastia. Case 6: 46-year-old Chinese male, BMI 27.0; ASPS grade 2 gynecomastia. (A) Pre-operative frontal view of Case 5; (B) pre-operative frontal view of Case 6. (C) Post-operative frontal view of Case 5; (D) post-operative frontal view of Case 6. The post-operative images illustrate the improvements in the patients' chest contours, with symmetric and natural-looking results that emphasize the underlying musculature and minimal body fat

[Downloaded from wjps.ir on 2026-11-25]

[DOI: 10.61882/wjps.14.3.101]

their appearance and experience heightened psychological distress in addition to their physical symptoms. To meet the high aesthetic expectations of this group, we perform precise 3-dimensional sculpting of the chest according to the individual's unique body shape and anatomical characteristics. This customized approach allows us to achieve good post-operative results with optimal musculature definition for the individual. As with other groups, our use of customized fine liposuction cannulas and strategic placement of incisions minimizes the risk of visible scars.

We illustrate our approach with two cases: a 22-year-old Malay male who had been using anabolic hormone supplements for bodybuilding for 4 years (ASPS grade 2; Figure 3A) and a 46-year-old Chinese male who took anabolic steroids for 5 years (ASPS grade 2, bilateral breast enlargement with slight asymmetry; Figure 3B). Both cases required bilateral breast gland excision and liposuction, done via a small, carefully placed peri-areolar incision. Due to the steroid-induced nature of the condition, special attention was given to addressing the full extent of the glandular tissue present prior to the sculpting step to achieve the desired symmetric and natural-looking chest contour, emphasizing the underlying musculature and minimal body fat (Figures 3C and 3D). A 3-month post-operative follow-up confirmed the absence of complications. Both patients expressed exceptional satisfaction with their aesthetic outcomes, giving it a score of 7 out of 7.

DISCUSSION

In our experience, the skin quality and glandular tissue characteristics of Asian patients with gynecomastia differ from those of their Caucasian counterparts, and this should be considered when planning treatment. The 6 cases presented here illustrate our approach to personalizing treatment for typical patient profiles in our practice. Among the 6 patients, only one experienced mild keloid formation, with no cases of hematoma or need for additional surgical corrections due to aesthetic dissatisfaction or post-surgical complications. All the patients expressed high satisfaction regarding the aesthetic results of the procedure.

Consistent with the existing literature [6-8] and our own observations, Asian patients tend to have thicker dermal layers than Caucasians, offering benefits such as improved post-surgical skin tightening and adaptation to breast volume reduction, which help achieve a natural-looking contour, even in cases of grade 3-4 gynecomastia. On the other hand, Asian patients are prone to developing pigmented and/or hypertrophic scars and having post-surgical scar adhesions, necessitating careful planning of the number, location, and size of incisions to optimize aesthetic outcomes and effectively manage risks. Additionally, glandular tissues in Asian patients, which tend to be more fibrous and often extend into the lateral and superior-lateral areolar regions, require thorough exploration of these regions for complete excision. The increased vascularity of this fibrous tissue also requires careful hemostasis to minimize the risk of post-surgical hematoma, highlighting the importance of careful post-operative management and follow-up.

Lastly, sensitive management of patient expectations is key to achieving desired overall outcomes and satisfaction with aesthetic treatments. Patients with realistic expectations are more likely to adhere to essential pre- and post-surgical advice [10], thereby enhancing the likelihood of favorable results.

CONCLUSION

Our clinical experience illustrates the value of customizing gynecomastia surgical approaches to take into account ethnic, clinical, and other characteristics to achieve good aesthetic outcomes in diverse populations. Further exploration and research would be desirable to optimize surgical strategies for non-Caucasian individuals and further understand the relationship between ethnic skin properties and healing patterns in gynecomastia surgery.

INFORMED CONSENT

All patients gave their informed consent authorizing the use and disclosure of their anonymized health information for this case report.

CONFLICT OF INTEREST

The author declares no relevant conflicts of interest associated with this manuscript.

[Downloaded from wjps.ir on 2026-11-25]

[DOI: 10.61882/wjps.14.3.101]

REFERENCES

1. Swerdloff RS, Ng JCM. Gynecomastia: Etiology, Diagnosis, and Treatment. In: Feingold KR, Anawalt B, Blackman MR, et al., editors. Endotext. South Dartmouth (MA): MDText.com, Inc.; 2000.
2. Barros AC, Sampaio Mde C. Gynecomastia: physiopathology, evaluation and treatment. *Sao Paulo Med J* 2012;**130**(3):187-97.
3. Ho SGY, Chan HHL. The Asian Dermatologic Patient. *Am J Clin Dermatol* 2009 2009/06/01;**10**(3):153-68.
4. Chan IL, Cohen S, da Cunha MG, Maluf LC. Characteristics and management of Asian skin. *Int J Dermatol* 2019 Feb;**58**(2):131-43.
5. Bayat A, Bock O, Mrowietz U, Ollier WE, Ferguson MW. Genetic susceptibility to keloid disease and hypertrophic scarring: transforming growth factor beta1 common polymorphisms and plasma levels. *Plast Reconstr Surg* 2003 Feb;**111**(2):535-43; discussion 44-6.
6. Fanous N, Côté V, Fanous A. The new Genetico-Racial Skin Classification: How to maximize the safety of any peel or laser treatment on any Asian, Caucasian or Black patient. *Can J Plast Surg* 2011 Spring;**19**(1):9-16.
7. McCurdy JA, Jr. Considerations in Asian cosmetic surgery. *Facial Plast Surg Clin North Am* 2007 Aug;**15**(3):387-97, vii.
8. Sykes JM. Management of the aging face in the Asian patient. *Facial Plast Surg Clin North Am* 2007 Aug;**15**(3):353-60, vi-vii.
9. American Society of Plastic Surgeons. ASPS Recommended Insurance Coverage Criteria for Third-Party Payers: Gynecomastia. 2002 (affirmed 2015); https://www.plasticsurgery.org/Documents/Health-Policy/Positions/Gynecomastia_ICC.pdf Accessed January 3, 2024
10. Chambers A. Management of Scarring Following Aesthetic Surgery. In: Téot L MT, Middelkoop E, et al.,, editor. Textbook on Scar Management: State of the Art Management and Emerging Technologies: Cham (CH): Springer; 2020; 2020.

[Downloaded from wjps.ir on 2026-11-25]

[DOI: 10.61882/wjps.14.3.101]