Case Report

Aplasia Cutis Congenita of the Scalp with a Familial Pattern: A Case Report

Waleed AlShehri, Sara AlFadil*, Alhanouf AlOthri, Abdulaziz O. Alabdulkarim, Shabeer A. Wani, Sari M. Rabah

Department of Plastic and Reconstructive Surgery, King Fahd Medical City, Riyadh, Saudi Arabia

***Corresponding Author:**
Sara AlFadil, MD
Scholar Resident Physician,
Department of Plastic and Reconstructive Surgery,
King Fahd Medical City,
Riyadh, Saudi Arabia
Tel: +96-6564004556
Fax: +96-6112889999 Ext 1393
Email: Sara.AlFadil@hotmail.com
Received: February 11, 2016
Revised: May 31, 2016
Accepted: June 4, 2016

ABSTRACT

Aplasia Cutis Conginita (ACC) is a condition characterized by congenital absence of skin, usually on the scalp. ACC can occur as an isolated condition or in the presence of other congenital anomalies. Here we describe a case of a 16 days old baby girl with an isolated ACC of the scalp. Her elder two siblings have been diagnosed with ACC with concomitant cardiac or limb anomalies. The patient was managed conservatively until the defect has scarred 6 months later.

KEYWORDS
Aplasia cutis congenita; Scalp; Reconstruction; Familial

Please cite this paper as:
AlShehri W, AlFadil S, AlOthri A, Alabdulkarim AO, Wani SA, Rabah SM. Aplasia Cutis Congenita of the Scalp with a Familial Pattern: A Case Report. World J Plast Surg 2016;5(3):298-302.

INTRODUCTION

Cutis aplasia or Aplasia Cutis Congenita (ACC) is an uncommon and rare congenital abnormality involving variant layers of the skin, mostly as a solitary lesions involving the midline over the skull vertex; and less commonly, underlying periosteum and bone.[1] Other sites may occur as well on the chest, abdomen or limbs.[2,3] Of lesions on the scalp, 20% can involve the cranium, exposing the underlying dura membrane. ACC could also be found in other congenital anomalies; since it was first described in 1767 by Cordon, around 500 similar cases have been reported so far.[4] Different anomalies were classified into 9 groups based on the number and the presence or absence of other anomalies (Table 1).[5] The lesions in those cases are quite variable, ranging from only local absence of skin to a complete absence of epidermis, subcutaneous tissue, bone, or in some cases the dura.[6-8] The incidence of ACC is estimated as 1 per 10,000 live births.[1]

This failure of formation is frequently more observed in females. The etiology remains unclear so far; however, both genetic and environmental causes have been implicated, including vascular blood supply, a sudden arrest of midline embryological development, failure in neural tube closure, and syphilis have at one time contributed as the cause.[1,9] Rupture of amniotic membrane in an early time, forming amniotic bands, may also be from the cause.[5] A number of teratogenic drugs such

[Downloaded from wjps.ir on 2026-11-24]

Table 1: Classification for ACC

Group		Associated Anomalies	Inheritance
1	Scalp ACC without multiple anomalies	Cleft lip and palate, tracheoesophageal fistula, patent ductus arteriosus, omphalocele, mental retardation, polycystic kidneys	Autosomal dominant or sporadic
2	Scalp ACC with limb abnormalities	Limbs reduced, syndactyly, clubfoot, encephalocele, nail dystrophy or absence, persistent cutis marmorata	Autosomal dominant
3	Scalp ACC with skin/ organoid nevi	Epidermal nevi, organoid nevi, corneal opacities, scleral dermoids, eyelid colobomas, mental retardation, seizures	Sporadic
4	ACC overlying embryologic malformations	Meningomyeloceles, spinal dysraphia, cranial stenosis, leptomeningeal angiomatosis, gastroschisis, congenital midline porencephaly, ectopia of ear, omphalocele	Depends upon underlying condition
5	ACC with fetus papyraceus or placental infarcts	Single umbilical artery spastic developmental delay, spastic paralysis, clubbed hands and feet, amniotic bands	Sporadic
6	ACC associated with epidermolysis bullosa	Blistering of skin and/or mucous membranes, deformed nails, pyloric or duodenal atresia, abnormal ears and nose, ureteral stenosis, renal anomalies, amniotic bands	Depends upon type of epidermolysis Bullosa
7	ACC localized to extremities without blistering	None	Autosomal Dominant or Recessive
8	ACC caused by teratogens	Imperforate anus (methimazole), other signs of intrauterine infection with varicella or herpes simplex	Not Inherited
9	ACC associated with congenital syndromes	Trisomy 13, 4p-syndrome, ectodermal dysplasias, ocal dermal hypoplasia, amniotic band disruption omplex, XY gonadal dysgenesis, Johanson-Blizzard syndrome	Depends upon syndrome

as methimazole, is a thiomedazole derivative used as an anti-thyroid agent, have shown to be involved.[10-13]

There are similar cases, classified as being of an autosomal dominant inheritance.[14] Establishing a diagnosis is usually based on the findings of the clinical examination, typically presenting as a hairless, smooth skin defect covered up by atrophic tissue or a dark-colored eschar. Superficial defects presenting as an ulcer are usually treated conservatively. Extensive or deep defects may require reconstruction of the scalp area or the use of bone transplants. However, hairless or scarcely haired scars mandate excision of the lesion and covering it with local flap from the scalp.[9,15-20]

CASE REPORT

A 16 days old newborn female from Saudi Arabia was presented to the clinic with a skin defect localized on the scalp since birth. The baby did not suffer from any ailments, and her medical history was unremarkable. Her mother, 32 years old, denied any history of illnesses during her pregnancy, infection or drug intake taking including Non-Steroidal Anti-Inflammatory Drugs (NSAID) or methimazole. She completed 38 weeks of gestation, and delivered her baby via a normal vaginal delivery.

The newborn did not sustain any birth injury and did not suffer from any other abnormalities or feeding difficulties. She did not require any intensive care, and went home from hospital with her mother. Upon local examination, the defect was solitary, localized with an irregular shape and approximately 6×6 cm in size (Figure 1). The lesion involved the epidermis and the upper dermis only. Neurosurgical team was involved in the care of this patient. A CT Scan of the head was performed, and no deep tissue involvement was noted.

Reconstruction solutions were offered to the parents but they insisted on non-surgical intervention. Therefore, the patient was treated with non-invasive debridement of the lesion and

[Downloaded from wjps.ir on 2026-11-24]

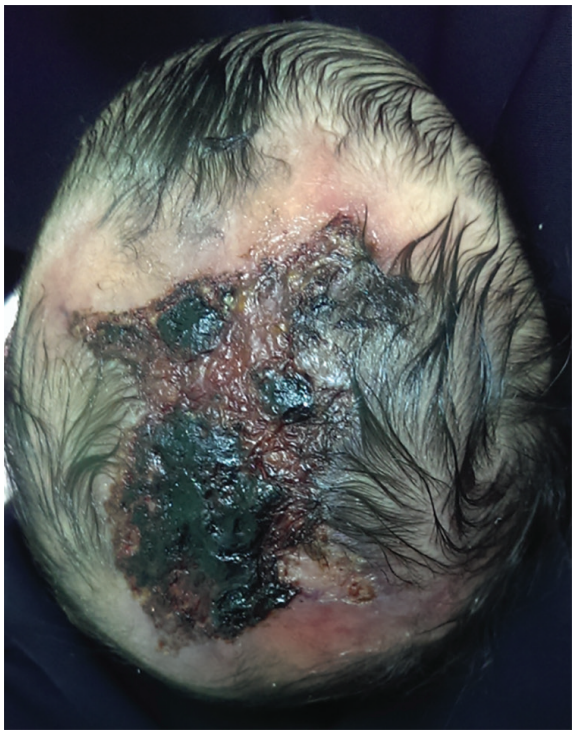

Fig. 1: The newborn presented with skin defect of the scalp with an overlying crust.



Fig. 2: Six months follow up shoes scar formation over the affected area.

local therapy, including gentle water cleansing and the application of topical antibiotic ointment. 6 months later, the patient has returned for a follow up. Scar tissue has formed over the defect (Figure 2). Family history revealed that none of her parents had the same condition; however, two of her sisters did, and were diagnosed with cutis aplasia. The elder one is currently 4 years of age, with right unilateral terminal reduction of the first and second toes (Figure 3). The other sister was born prematurely and died shortly after birth due to cardiac anomalies.

DISCUSSION

ACC occurs as a solitary defect, it can happen alone or in the presence of syndromic congenital anomalies. The involvement of the scalp area may lead to the understanding of the etiology. Upon our review to the literature available, cases were often characterized by an entire absence of skin and subcutaneous tissues. Histologically, we found that most of the lacking tissues belonged to epithelial ectoderm. The condition could be associated with Chromosomal defects.[21] Some researches showed the association with gestational conditions such as an intrauterine vascular ischemia, amniotic adherences, and viral infections.[22,23]



Fig. 3: Unilateral terminal reduction of the right first and second tow.

A rise of alpha-fetoprotein levels and a distinct amniotic fluid acetylcholine sterase band were found in recent article as markers for ACC.[24] Also a number of drugs have been linked to ACC. For example, the use of cocaine during pregnancy can lead to vasoconstriction of the placenta or disruption of the fetus vascularity, causing the cranial defects and anomalies of the central nervous system (CNS).[25] Methimazole, a

[Downloaded from wjps.ir on 2026-11-24]

drug used for the treatment of hyperthyroidism, may show some skin affection.

Benzodiazepines use is also linked with ACC.[7] Surgical treatment requires careful preoperative planning.[26] Minimal superficial lesions are treated conservatively to heal gradually by re-epithelialization and result with a hypertrophic or atrophic scar. Tissue expander insertion may be necessary in extensive lesions reaching the scalp; whereas the one deep enough to reach brain, bone and meningeal transplants may be indicated.[9,15,20,27] Deep defects overlying the sagittal sinus are indicators for urgent surgical intervention to prevent potentially lethal infections or hemorrhage.[28-30]

Grafting,[31] biological dressings use temporarily,[32] and silver sulfadiazine dressings while waiting for the processes of skin and bony ingrowth have been published with variable degree of success.[33]

CONFLICT OF INTEREST

The authors declare no conflict of interest.

REFERANCES

1 Bajpai M, Pal K. Aplasia cutis cerebri with partial acrania- total reconstruction in a severe case and review of the literature. *J Pediatr Surg* 2003;**38**:e4.

2 O'Neill JK, Carter M, Warr RP. Aplasia cutis congenita: a case of scalp defect repair using two opposing bipedicled local flaps. *J Plast Reconstr Aesthet Surg* 2010;**63**:e242-e4.

3 Blunt K, Quan V, Carr D, Paes BA. Aplasia cutis congenita: a clinical review and associated defects. *Neonatal Netw* 1992;**11**:17-27.

4 Cordon M. Extrait d'une lettre au sujet de trois enfants de la même mère nés avec partie des extrémités dénuée de peau. *J Med Chir Pharm* 1767;**26**:556-7.

5 Frieden IJ. Aplasia cutis congenita: a clinical review and proposal for classification. *J Am Acad Dermatol* 1986;**14**:646-60.

6 L.P. Lassman, D.G. Sims, Congenital midline scalp and skull defects. *Arch Dis Child* 1950;**50**:958-60.

7 Martı´nez-Lage JF, Almagro MJ, Herna´ ndez F.L., Poza M. Aplasia cutis congenital of the scalp. *Childs Nerv Syst* 2002;**18**:634–7.

8 Aloulou H, Chaari W, Khanfir S, Zroud N, Kammoun TH, Abdelmoula M, Hachicha M. Aplasia cutis congenita of the scalp (5 observations). *Arch Pediatr* 2008;**15**:382–7.

9 Argenta LC, Dingman RO. Total reconstruction of aplasia cutis congenita involving scalp, skull and dura. *Plast Reconstr Surg* 1986;**77**:650-3.

10 Inoue M, Arata N, Koren G, Ito S. Hyperthyroidism during pregnancy. *Can Fam Physician* 2009;**55**:701–3.

11 Iwayama H, Hosono H, Yamamoto H, Oshiro M, Ueda N. Aplasia cutis congenita with skull defect in a monozygotic twin after exposure to methimazole in utero. *Birth Defects Res A Clin Mol Teratol* 2007;**79**:680–4.

12 Abe M, Syuto T, Yokoyama Y, Ishikawa O. Aplasia cutis congenital after methimazole exposure in utero successfully treated with basic fibroblast growth factor. *Int J Dermatol* 2010;**49**:334–5.

13 Baid SK, Merke DP. Aplasia cutis congenita following in utero methimazole exposure. *J Pediatr Endocrinol Metab* 2007;**20**:585–6.

14 Chitnis MR, Carachi R, Galea P. Familial aplasia cutis congenita. *Eur J Pediatr Sturg* 1996;**6**:100-1.

15 Attalla MF, el Sayed AM. Scalp aplasia cutis congenita: closure by the L-shaped flap. *Childs Nerv Syst* 1992;**8**:287-8.

16 Borguolo O, Longo F, Olivo G, Guidobaldi G. Aplasia cutis congenita: report of 4 additional cases and review of the literature (in italian). *Pediatr Med Chir* 1994;**16**:559-63.

17 Kruk-Jeromin J, Lewandowicz E. Congenital aplasia of scalp skin. *Przegl Dermatol* 1986;**73**:908-11.

18 Ross DA, Laurie SW, Coombs CJ, Mutimer KL. Aplasia cutis congenita: failed conservative treatment. *Plast Reconstr Surg* 1995; **95**:124-9.

19 Field LM. Scalp flaps. *J Dermatol Surg Oncol* 1991;**17**:190-9.

20 McCarthy JG. Plastic Surgery. Philadelphia: Saunders Co. 1990; pp. 91-5, 1516-73.

21 Honore LH, Dill FJ, Foland BJ. Placental morphology in spontaneous human abortuses with normal and abnormal karyotypes, *Teratology* 2006;**14**:151–66.

22 Mannino FL, Jones KL, Benirschke K. Congenital skin defects and fetus papyraceous. *J Pediatr* 1977;**91**:559–64.

23 Evers ME, Steijlen PM, Hamel BC. Aplasia cutis congenital and associated disorders: an update. *Clin Genet* 1995;**47**:295–301.

[Downloaded from wjps.ir on 2026-11-24]

24 Dror Y, Gelman-Kohan Z, Hagai Z, Juster-Reicher A, Cohen RN, Mogilner B. Aplasia cutis congenita, elevated alpha-fetoprotein, and a distinct amniotic fluid acetylcholinesterase electrophoretic band. *Am J Perinatol* 1994;**11**:149–52.
25 Whitley C.B., Gorlin R.J. Adams-Oliver syndrome revisited. *Am J Med Genet* 1991;**40**:319–26.
26 Goldberg C, Fenelon G, Balke NS, Dowling F, Regan BF. Diastematomyelia: A clinical review of the naturel history and treatment. *Spine* 1984;**9**:367-72.
27 Dyall-Smith D, Ramsden A, Laurie S. Adams-Oliver syndrome: aplasia cutis congenita, terminal transverse limb defects and cutis marmorata telangiectatica congenita. *Australas J Dermatol* 1994;**35**:19-22.
28 Peer LA, Duyn JV. Congenital defect of the scalp: report of a case with fatal termination. *Plast Reconstr Surg* 1948;**3**:722–3.
29 Kosnik EJ, Sayers MP. Congenital scalp defects: aplasia cutis congenita. *J Neurosurg* 1975;**42**:32–6.
30 Sargent LA. Aplasia cutis congenita of the scalp. *J Ped Surg* 1990;**25**:1211–13.
31 Bailie FB. Aplasia cutis congenita of neck and shoulder requiring a skin graft: a case report. *Br J Plast Surg* 1983;**36**:72–4.
32 Lambert J, Govaert P, Naeyaert JM. What syndrome is this? *Ped Derm* 1997;**14**:330–2.
33 Blunk K, Quan V, Carr C. Aplasia cutis congenita: a clinical review and associated defects. *Neonatal Network* 1992;**11**:17–27.

[Downloaded from wjps.ir on 2026-11-24]