

Effect of Systemic Antioxidant Allopurinol Therapy on Skin Flap Survival

Mehdi Rasti Ardakani¹, Ahmed Al-Dam², Ashkan Rashad², Ali Shayesteh Moghadam^{1*}

1. Department of Plastic Surgery, Isfahan University of Medical Sciences, Isfahan, Iran;

2. Department of Oral and Maxillofacial Surgery, University Medical Center Hamburg-Eppendorf, Hamburg, Germany

ABSTRACT

BACKGROUND

It has been reported that systemic administration of allopurinol improves cell survival. This study was aimed to evaluate effects of allopurinol on skin flaps in dogs.

METHODS

Twenty dogs underwent one skin flap surgery with a 2-week interval. The first procedure was performed according to the standard protocols. The second phase was started by a 1-week pretreatment with allopurinol. Length of the necrotic zone was measured and recorded daily. At each phase, flaps were removed and sent for histopathological study after 1 week observation.

RESULTS

Mean length of the necrotic zone in allopurinol treated skin flaps has been significantly less than normal flaps over all 7 days of observation ($p < 0.0001$). Histopathology study showed less inflammation and more normal tissue structure in the allopurinol treated skin flaps.

CONCLUSION

It was demonstrated that systemic administration of allopurinol significantly improved skin flap survival.

KEYWORDS

Allopurinol; Antioxidant; Skin flap; Survival

Please cite this paper as:

Rasti Ardakani M, Al-Dam A, Rashad A, Shayesteh Moghadam A. Effect of Systemic Antioxidant Allopurinol Therapy on Skin Flap Survival. *World J Plast Surg* 2017;6(1):54-61.

INTRODUCTION

Skin flaps are increasingly used by plastic surgeons to reconstruct tissue defects resulting from trauma, ablative surgery or congenital malformation. Nevertheless, necrosis is still a serious complication which may affect skin flap survival.^{1,2} Despite remarkable progress in plastic surgery over the previous two decades, flap surgery is still associated with a notable morbidity. Total loss occurs in 1-5% of cases even in flaps which are microscurgically transferred by skilled surgeons.³⁻⁵ In addition, partial flap necrosis has been reported in 7-20% of free flaps and 20-33% of pedicled flaps.⁶⁻⁹

Post surgical ischemia-reperfusion (IR) injury is one of the most important causes of flap damage. IR injury may cause

*Corresponding Author:

ALi Shayesteh Moghadam, MD;
Department of Plastic Surgery,
Medical Education Research Center,
Isfahan University of Medical Sciences,
Isfahan, Iran

E-mail: a.shayesteh3@gmail.com

Received: October 17, 2015

Revised: July 23, 2016

Accepted: August 24, 2016

clinical problems for medical professions and prolonged hospitalization which increases medical costs.¹⁰⁻¹² Neutrophil infiltration and production of superoxide free radicals are 2 major events which occur during IR, and lead to tissue injury.^{13,14} Xanthine oxidase (XO) plays an important role in the pathogenesis of IR injury. There is a significant up-regulation of XO system during ischemia of skin flaps.^{15,16}

XO is a major source of reactive oxygen species (ROS) which triggers release of several inflammatory mediators.^{17,18} Allopurinol is an antioxidant drug, and inhibits XO. Hence, systemic administration of allopurinol reduces ROS formation and may improve survival rate of skin flaps.^{19,20} However, effectiveness of allopurinol in improving skin flap survival is still controversial.^{21,22} Combination of the above evidence and the necessity of finding an effective method to improve skin flap survival led us to design this study to evaluate effects of allopurinol on skin flaps in dogs.

MATERIALS AND METHODS

This clinical trial was performed at veterinary hospital of our university medical centre. The study was approved by the local ethics committee (391136) and the guidelines of the Helsinki Declaration have been followed for this investigation. Twenty male, healthy, mix dogs aged between 3 to 4 years by the mean weight of 5.4 kg were included in the present study. All dogs had physical examination prior to the study. They had been completely vaccinated, and had received a complete course of anti parasite medication. All dogs were kept in separate cages during the study and were fed with normal diet.

In this study the dogs were divided to two groups of ten (Group A and B). All dogs underwent one skin flap surgery by a single blinded surgeon (a total number of 20 skin flaps). Group A (control group) procedure was performed under the standard conditions with no additional medication. Group B procedure was performed similar to the first one, but all dogs were pre-treated with unlabeled use of oral allopurinol from one week before the surgery until 48 hours after skin flap surgery.

In Group A as skin flap surgery group, after 12 hours of fasting, the surgical site (the back of the dogs) was shaved. Dogs were anaesthetized with ketamine (75 mg/kg of body weight) and a

cuffed endotracheal tube was inserted into the trachea. Then an island adipofascial cutaneous flap, 4×24 cm, was created in one side of the spinal column. Afterwards, the flap was sutured in place immediately using simple interrupted nylon-01 sutures (Figure 1).

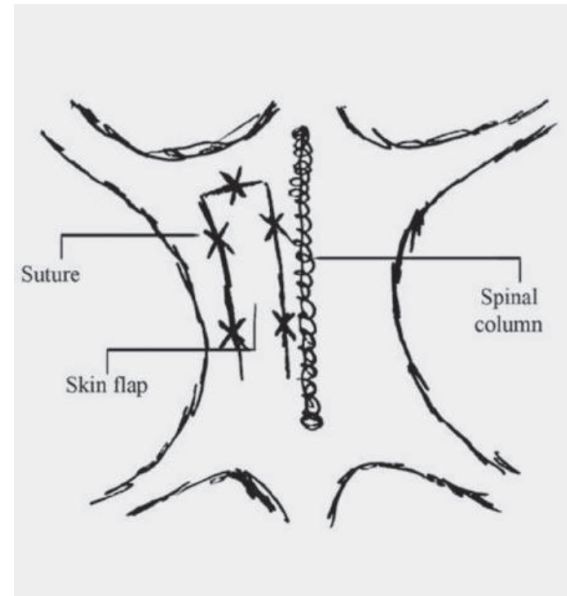


Fig. 1: Schematic view of the surgical site and sutures' sites.

After the operation dogs were treated with appropriate dose of analgetics. In addition, 60 min before surgery and a daily dose of 30 mg/kg Cefazolin after surgery was commenced intravenously. All dogs were being visited over the first week after the operation on a daily basis by a veterinarian and the surgeon to check the general condition and skin flap status. At the end of this one week observation flaps were removed. After removal, flap site was closed with simple continuous suture of nylon-01.

In Group B as skin flap surgery group, all ten dogs in second group received allopurinol (MD-Allopurinol ® 100 mg, Mehr Darou, Tehran, Iran, daily dose of 50 mg/kg of body weight) through the nasogastric tube for 9 days (7 days prior to surgery, 2 days during the observation). Skin flap surgery was performed one week after commencing allopurinol. Otherwise, the second operation was completely similar to the first group one.

Regarding measurements, all flaps were assessed daily regarding the size of the necrotic area. After allowing the skin to lie in the natural position, length of the necrotic area was measured by the surgeon, using a single

standard digital ruler with the accuracy of 1/100 centimeter. All measurements were recorded in cm. Length of the necrotic zone was defined as the longest distance between the necrotic edge and the survived area. Care was taken to ensure maintenance of a straight line during the measurement.

For pathologic study of the skin flaps, one week after each skin flap surgery, the skin flaps were removed, fixed in 10% formalin and sent for histopathological study. After hematoxylin and eosin (H&E) and toluidine blue staining, all samples were investigated by a single pathologist who was unaware of the type of treatment. Samples were studied regarding the number of neutrophils, fibroblasts, mast cells and other inflammatory cells, using a light microscope. Data was analyzed by SPSS 16.5 software. Independent-t test was used to compare mean length of necrotic zone between standard flaps and allopurinol treated flaps. P-values less than 0.05 were considered as the level of significance.

RESULTS

Comparison of two types of skin flaps showed that mean length of the necrotic zone in allopurinol treated skin flaps have been significantly less than normal flaps over all 7 days of observation (Table 1). Figure 2 illustrates the changes of necrotic zone for both groups during observation time. Differences in length of necrotic zones even increased with continually growing observation time. Figure 3 and 4 represent skin flaps treated with allopurinol whereas Figure 5 and 6 show control group flaps.

Regarding normal skin flaps findings of different zones, (i) necrotic zone findings: Coagulative necrosis with large amounts of vessel thrombosis can be detected. A few neutrophils and fibrotic tissue in margins were seen (Figure 7a). (ii) Transitional zone findings: Destruction of the epidermis in most of the regions. In superficial dermis there was infiltration of inflammatory cells- mostly

Table 1: Comparison of mean length of necrotic zone between two types of flaps in different days

	Mean length of the necrotic zone (cm)						
	Day 1	Day 2	Day 3	Day 4	Day 5	Day 6	Day 7
Normal skin flaps (n=10)	5.92±0.66	9.14±0.75	12.77±0.56	15.35±0.63	17.41±0.75	18.50±0.80	19.44±0.77
Allopurinol treated skin flaps (n=10)	2.41±0.33	3.26±0.42	3.93±0.54	4.49±0.62	5.03±0.67	5.51±0.67	5.87±0.63
p value	<0.0001	<0.0001	<0.0001	<0.0001	<0.0001	<0.0001	<0.0001

Data are presented as mean±SD length of the necrotic zone, in cm, during the observation time. N=number of cases; SD=Standard deviation

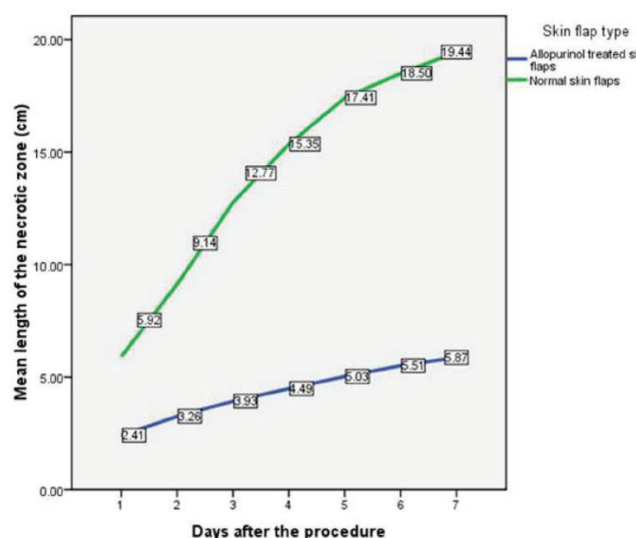


Fig. 2: Illustration of changes in the mean length of necrotic zone in both groups. Data are presented as mean length of necrotic zone in cm in different days.

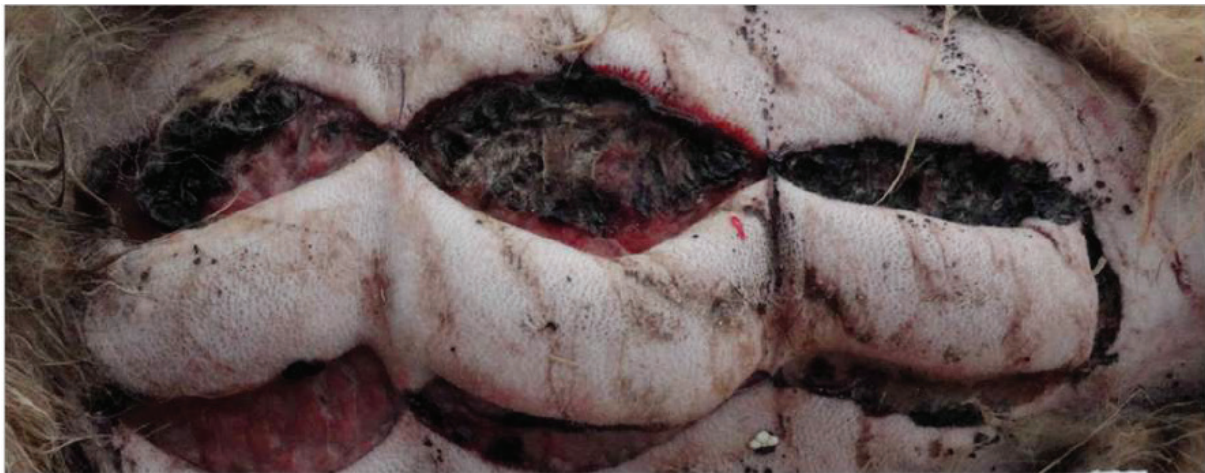

Fig. 3: Postoperative view on allopurinol treated dog without necrotic area.

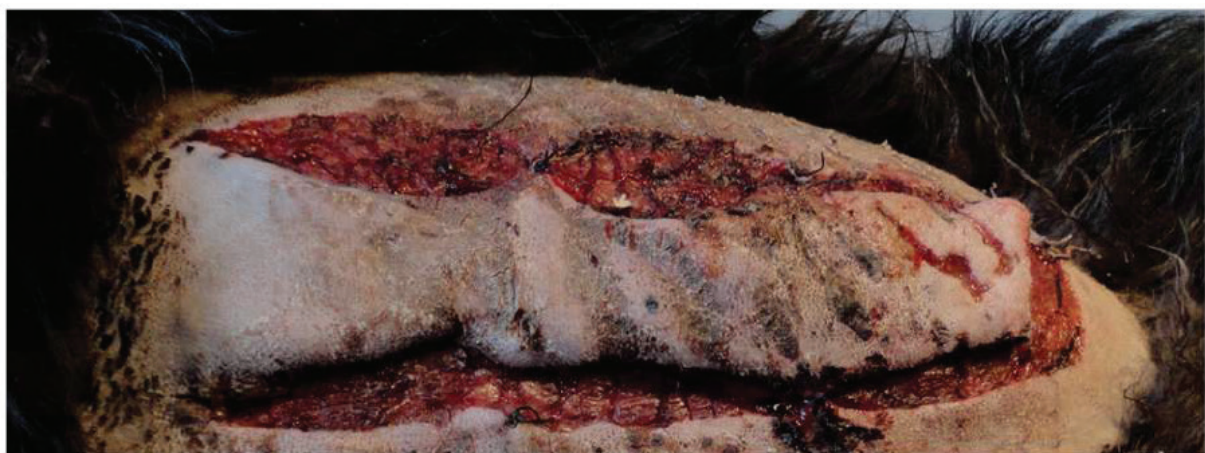

Fig. 4: Vital flap mainly supplied by the basis allocated in allopurinol treated group.

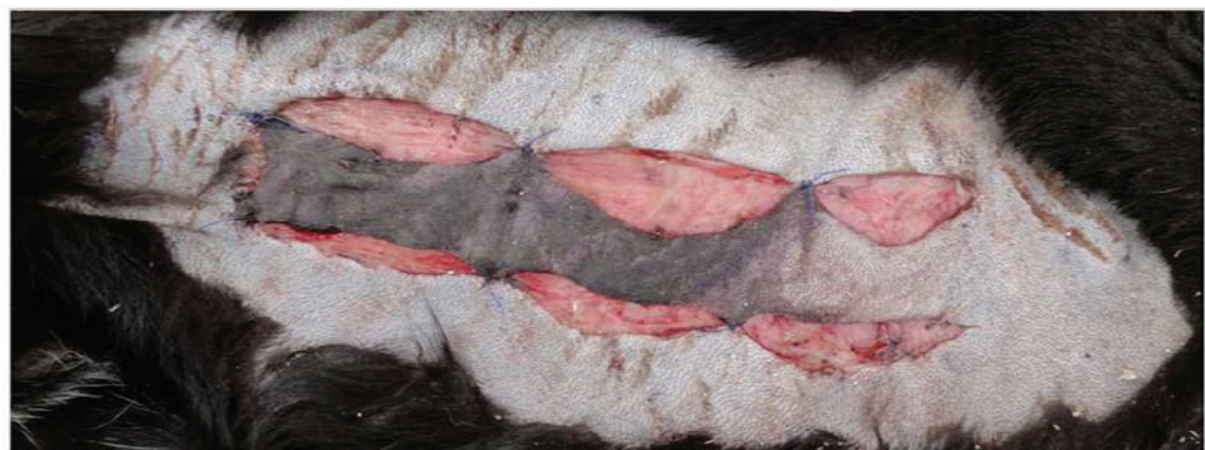

Fig. 5: About two thirds of the base distant flap outlined to be necrotic without any allopurinol administration.

neutrophils- between collagen bundles. Existing microabscess. More severe inflammation was found in the subcutis fat in form of non-septal panniculitis. Fat necrosis with intensive infiltration of inflammatory cells - neutrophils, macrophage and lymphoplasma cells could be detected. Numerous dilated vessels with evidence of thrombosis in some of them were present

(Figure 7b). (iii) Intact zone findings: Moderate infiltration of inflammatory cells- macrophage and plasma cells - in the subcutaneous fat and deep dermis. There was focal fat necrosis. Furthermore existing extravasation of red blood cells and vasodilatation (Figure 7c).

Regarding allopurinol treated skin flaps findings of different zones, (i) Necrotic zone

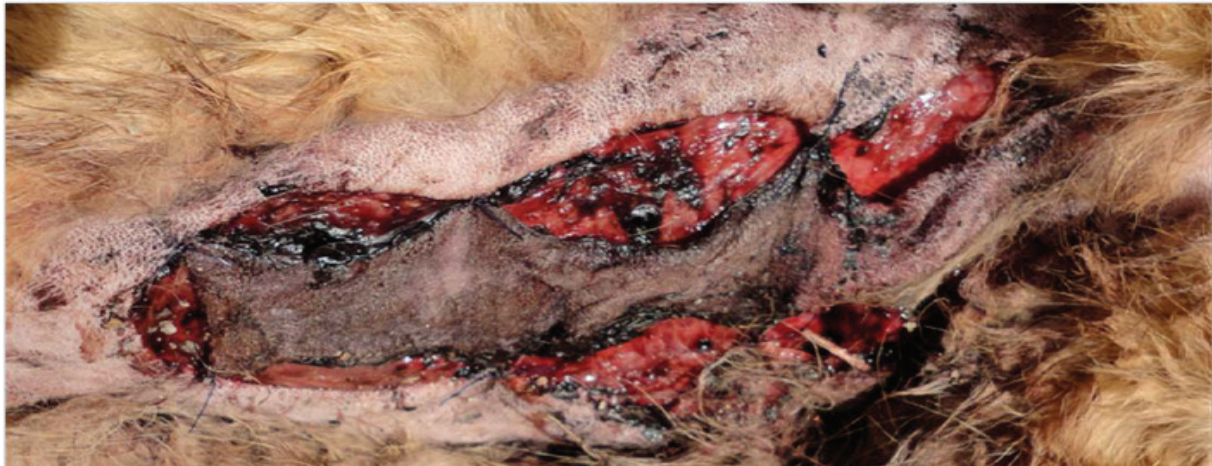

Fig. 6: Insufficiently perfused flap of control group without any medication treatment.

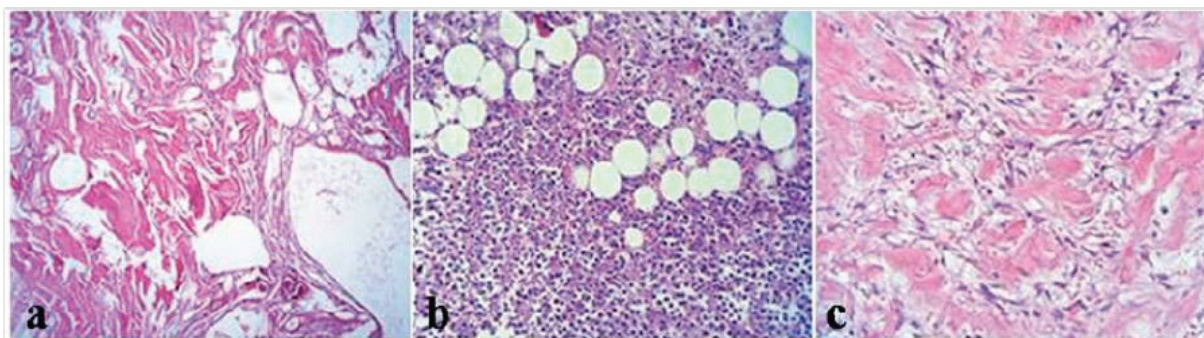


Fig. 7: Histopathological findings of different zones of normal skin flap 7 days after skin flap surgery. A: necrotic zone, B: transitional zone, C: intact zone.

findings: Shedding of the superficial epidermis. Intensive infiltration of inflammatory cells - neutrophils and macrophage - around the muscle bundles with focal microabscess and dilated vessels and thrombosis in some of them (Figure 8a). (ii) Transitional zone findings: Focal shedding of the epidermis accompanied by mild infiltration of neutrophils. Obvious red blood cell extravasation in superficial dermis. Severe panniculitis, fat necrosis, infiltration of neutrophils and dilated vessels with some thrombosis were seen in the deep dermis (Figure 8b). (iii) Intact zone findings: Completely normal structure of the skin tissue (Figure 8c).

DISCUSSION

Despite several treatment strategies which aim at reducing or preventing skin flap necrosis, improvement of the flap survival is still an important concern for surgeons. This study showed that pre-/ and post-treatment with allopurinol leads to significant reduction of the necrotic zone length, more normal histological

structure and less inflammation of the skin tissue in dogs. Allopurinol has been primarily used for treatment of hyperuricemia and gout,²³ but based on its mechanism of action and its effects on endothelial function, it has been investigated as a novel medication for other medical problems.²⁴⁻²⁷ Effects of allopurinol on survival of skin flaps are related to its mechanism of action and mechanisms which cause tissue damage. IR injury has been considered as one of the major causes of skin flap damage.²⁸

ROS including oxygen ions, free radicals and peroxides are generated during ischemic phase and especially during reperfusion. The production of ROS over the reperfusion phase results in endothelial cell swelling, vasoconstriction and increased capillary permeability which impairs the microcirculation.^{20,29} ROS are usually produced by two major mechanisms: The Nicotinamide Adenine Dinucleotide Phosphate (NADPH) oxidase system in neutrophils and the XO system in endothelium cells.^{12,30,31} The XO system appears to be a major source of ROS.^{12,32-34} The activity of this system significantly

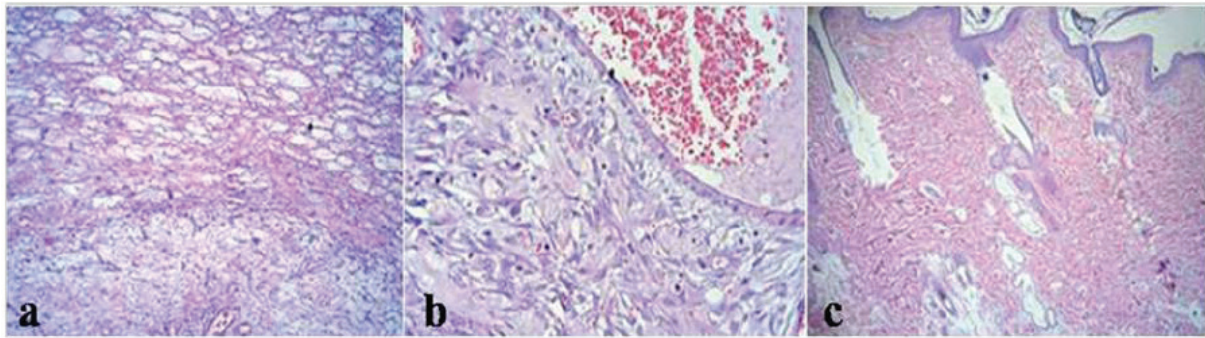


Fig. 8: Histopathological findings of different zones of allopurinol treated skin flap 7 days after skin flap surgery. A: necrotic zone, B: transitional zone, C: intact zone.

increases during the ischemia, and produces a large amount of ROS.²⁰ Therefore, it is not surprising to find that systemic administration of an XO inhibitor such as allopurinol improves skin flap survival.

A previous study performed by Tamir *et al.* confirms our findings by a different study design in rats. They investigated effects of allopurinol on survival of island skin grafts under prolonged period of ischemia and found it a useful method to improve skin flap survival.²⁸ They believe that pre-treatment with allopurinol enables skin grafts to tolerate longer periods of ischemia. This effect is contributed to the XO inhibitor properties of allopurinol. Another study by Im *et al.* also reported that allopurinol can improve skin flap survival in rats by inhibiting most of the increased activity of XO during IR, and consequently, by preventing tissue damage.³⁵

Picard-Ami *et al.* reported different levels of XO activity in rats, pigs and humans.³⁶ Therefore, in contrast to the above mentioned studies, they studied effects of allopurinol on skin flaps of pigs and found it ineffective.²² This finding shows that although allopurinol can improve skin flap survival by reducing ROS levels, this effect is completely dependent on the level of XO activity in the target organ. Even though critical flap monitoring is within 72 hours postoperatively,³⁷ we did monitor the flaps over 1 week. Nevertheless our study lacks an extended observation period and thus no statement can be made regarding long-term survival.

The present experiment had some critical differences with aforementioned studies. Instead of rats which are most commonly used to investigate this subject, we used dogs. Accordingly, flaps could be dimensioned generously comparable to humans with no

size limitation as for rats. More importantly, in contrast to the previous studies in which allopurinol was administrated a few hours before²² to or even after the procedure,²⁸ in this study dogs were pre-treated with allopurinol for 1 week prior to the surgery which helped us to reach a steady plasma concentration of the drug.

In summary, findings obtained from our study demonstrated that systemic administration of allopurinol significantly improved skin flap survival and had a protective effect against flap necrosis in dogs. Clinical impressions were confirmed by histopathological examination. Although results of this method regarding administration of allopurinol are promising, further studies - such as comparison of XO activity of dogs with humans - are required prior to apply it on humans. Furthermore, studies with even smaller and larger dimensioned flaps should be done. Unfortunately, there is no uniform and practical way for worldwide use until now. Therefore further studies need to be done to reach a common method for make it practical.

ACKNOWLEDGEMENT

The authors declare no conflict of interests or source of funding.

CONFLICT OF INTEREST

The authors declare no conflict of interest.

REFERENCES

1. Akan M, Cakir B, Misirlioglu A, Yildirim S, Taylan G, Aköz T. Effects of clopidogrel and high dose aspirin on survival of skin flaps in rats. *Scand J Plast Reconstr Surg Hand Surg*

- 2005;**39**:7-10.
- 2 Torkvist L, Lofberg R, Raud J, Thorlacius H. Heparin protects against skin flap necrosis: relationship to neutrophil recruitment and anti-coagulant activity. *Inflamm Res* 2004;**53**:1-3.
- 3 Khouri RK, Cooley BC, Kunselman AR, Landis JR, Yeramian P, Ingram D, Natarajan N, Benes CO, Wallemark C. A prospective study of microvascular free- flap surgery and outcome. *Plast Reconstr Surg* 1998;**102**:711-21.
- 4 Moran SL, Nava G, Behnam AB, Serletti JM. An outcome analysis comparing the thoracodorsal and internal mammary vessels as recipient sites for microvascular breast reconstruction: a prospective study of 100 patients. *Plast Reconstr Surg* 2003;**111**:1876- 82.
- 5 Nahabedian MY, Momen B, Manson PN. Factors associated with anastomotic failure after microvascular reconstruction of the breast. *Plast Reconstr Surg* 2004;**114**:74-82.
- 6 Banic A, Boeckx W, Greulich M, et al. Late results of breast reconstruction with free TRAM flaps: a prospective multicentric study. *Plast Reconstr Surg* 1995;**95**:1195-204.
- 7 Moran SL, Serletti JM. Outcome comparison between free and pedicled TRAM flap breast reconstruction in the obese patient. *Plast Reconstr Surg* 2001;**108**:1954-60.
- 8 Tanaka N, Yamaguchi A, Ogi K, Kohama G. Sternocleidomastoid myocutaneous flap for intraoral reconstruction after resection of oral squamous cell carcinoma. *J Oral Maxillofac Surg* 2003;**61**:1179-83.
- 9 Wei FC, Celik N, Chen HC, Cheng MH, Huang WC. Combined anterolateral thigh flap and vascularized fibula osteoseptocutaneous flap in reconstruction of extensive composite mandibular defects. *Plast Reconstr Surg* 2002;**109**:45-52.
- 10 Cetin C, Kose AA, Aral E, Colak O, Erçel C, Karabağlı Y, Alataş O, Eker A. Protective effect of fucoidin (a neutrophil rolling inhibitor) on ischemia reperfusion injury: experimental study in rat epigastric island flaps. *Ann Plast Surg* 2001;**47**:540-6.
- 11 Rand-Luby L, Pommier RF, Williams ST, Woltering EA, Small KA, Fletcher WS. Improved outcome of surgical flaps treated with topical dimethylsulfoxide. *Ann Surg* 1996;**224**:583-9.
- 12 Kerrigan CL, Stotland MA. Ischemia reperfusion injury: a review. *Microsurgery* 1993;**14**:165-75.
- 13 Gute DC IT, Yarimizu K, Korrhuis RJ. Inflammatory responses to ischemia and reperfusion in skeletal muscle. *Mol Cell Biochem* 1998;**179**:169-87.
- 14 Gideroglu K, Alagoz S, Uygur F, Evinc R, Celikoz B, Bugdayci G. Effects of nebivolol on skin flap survival: A randomized experimental study in rats. *Curr Ther Res* 2008;**69**:449-58.
- 15 Im MJ, Hoopes JE, Yoshimura Y, Manson PN, Bulkley GB. Xanthine:acceptor oxidoreductase activities in ischemic rat skin flaps. *J Surg Res* 1989;**46**:230-4.
- 16 Angel MF, Im MJ, Chung HK, Vander Kolk CA, Manson PN. Effects of combined cold and hyperbaric oxygen storage on free flap survival. *Microsurgery* 1994;**15**:648-51.
- 17 Li C, Jackson RM. Reactive species mechanisms of cellular hypoxia-reoxygenation injury. *Am J Physiol Cell Physiol* 2002;**282**:227-41.
- 18 İlhan H, Alatas O, Tokar B, çOlak O, Paşaoğlu O, Koku N. Effects of the anti-ICAM-1 monoclonal antibody, allopurinol, and methylene blue on intestinal reperfusion injury. *J Pediatr Surg* 2003;**38**:1591-5.
- 19 Milcheski DA, Nakamoto HA, Tuma P, Nóbrega L, Ferreira MC. Experimental Model of Degloving Injury in Rats: Effect of Allopurinol and Pentoxifylline in Improving Viability of Avulsed Flaps. *Ann Plast Surg* 2013;**70**:366-9.
- 20 van den Heuvel MG, Buurman WA, Bast A, van der Hulst RR. Ischaemia-reperfusion injury in flap surgery. *J Plast Reconstr Aesthet Surg* 2009;**62**:721-6.
- 21 Rees R, Smith D, Li TD, et al. The role of xanthine oxidase and xanthine dehydrogenase in skin ischemia. *J Surg Res* 1994;**56**:162-7.
- 22 Picard-Ami LA Jr., MacKay A, Kerrigan CL. Effect of allopurinol on the survival of experimental pig flaps. *Plast Reconstr Surg* 1992;**89**:1098-103.
- 23 Rundles RW. The development of allopurinol. *Arch Intern Med* 1982;**145**:89-94.
- 24 Butler R, Morris AD, Belch JJ, Hill A, Struthers AD. Allopurinol normalizes endothelial dysfunction in type 2 diabetics with mild hypertension. *Hypertension* 2000;**35**:746-51.
- 25 Doehner W, Schoene N, Rauchhaus M, Leyva-Leon F, Pavitt DV, Reaveley DA, Schuler G, Coats AJ, Anker SD, Hambrecht R. Effects of xanthine oxidase inhibition with allopurinol

- on endothelial function and peripheral blood flow in hyperuricemic patients with chronic heart failure: results from 2 placebo-controlled studies. *Circulation* 2002;**105**:2619-24.
- 26 Farquharson CAJ, Butler R, Hill A, Belch JJ, Struthers AD. Allopurinol improves endothelial dysfunction in chronic heart failure. *Circulation* 2002;**106**:221-6.
 - 27 Guthikonda S, Sinkey C, Barenz T, Haynes WG. Xanthine oxidase inhibition reverses endothelial dysfunction in heavy smokers. *Circulation* 2003;**107**:416-21.
 - 28 Tamir G, Yaffe B, Pri-Chen S, Hauben DJ, Tsur H. The effect of allopurinol on experimental island skin flap survival under prolonged periods of arterial ischaemia. *Br J Plast Surg* 1994;**47**:155-7.
 - 29 Manson PN, Narayan KK, Im MJ, Bulkley GB, Hoopes JE. Improved survival in free skin flap transfers in rats. *Surgery* 1986;**99**:211-15.
 - 30 Siemionow M, Arslan E. Ischemia/reperfusion injury: a review in relation to free tissue transfers. *Microsurgery* 2004;**24**:468-75.
 - 31 Harder Y, Amon M, Laschke MW, Schramm R, Rücker M, Wettstein R, Bastiaanse J, Frick A, Machens HG, Küntscher M, Germann G, Vollmar B, Erni D, Menger MD. An old dream revitalised: preconditioning strategies to protect surgical flaps from critical ischaemia and ischaemia-reperfusion injury. *J Plast Reconstr Aesthet Surg* 2008;**61**:503-511.
 - 32 Ozmen S, Ayhan S, Demir Y, Siemionow M, Atabay K. Impact of gradual blood flow increase on ischaemia-reperfusion injury in the rat cremaster microcirculation model. *J Plast Reconstr Aesthet Surg* 2008;**61**:939-948.
 - 33 Feng GM, Yang WG, Huan-Tang Chen S, Chu YM, Tsai LM, Chang TM, Mardini S, Chen HC. Periodic alterations of jejunal mucosa morphology following free microvascular transfer for pharyngoesophageal reconstruction. *J Plast Reconstr Aesthet Surg* 2006;**59**:1312-17.
 - 34 Aydogan H, Gurlek A, Parlakpınar H, Askar I, Bay-Karabulut A, Aydogan N, Fariz A, Acet A. Beneficial effects of caffeic acid phenethyl ester (CAPE) on the ischaemia-reperfusion injury in rat skin flaps. *J Plast Reconstr Aesthet Surg* 2007;**60**:563-8.
 - 35 Im MJ, Shen WH, Pak CJ, Manson PN, Bulkley GB, Hoopes JE. Effect of allopurinol on the survival of hyperemic island skin flaps. *Plast Reconstr Surg* 1984;**73**:276-8.
 - 36 Picard-Ami LA, Jr., MacKay A, Kerrigan CL. Pathophysiology of ischemic skin flaps: differences in xanthine oxidase levels among rats, pigs, and humans. *Plast Reconstr Surg* 1991;**87**:750-5.
 - 37 Cornejo A, Ivatury S, Crane CN, Myers JG, Wang HT. Analysis of free flap complications and utilization of intensive care unit monitoring. *J Reconstr Microsurg* 2013;**29**:473-9.