

# Reverse Facial-Submental Artery Osteomyocutaneous Flap, a Novel Choice for Previously Operated Huge Alveolar Clefts

Mahdi Gholami<sup>1</sup>, Abdolrahim Shams<sup>2\*</sup>, Nafise Ghadirimoghaddam<sup>2</sup>, Hussein Khalife<sup>3</sup>

1. Department of Oral and Maxillofacial Surgery, School of Dentistry, Mashhad University of Medical Science, Mashhad, Iran
2. Oral and Maxillofacial Disease Research Center, Mashhad University of Medical Science, Mashhad, Iran
3. Oral and Maxillofacial Surgeon, Private Practice, Beirut, Lebanon

## ABSTRACT

Adult previously operated alveolar cleft palate presents a pronounced challenge for optimal surgical reconstruction. This optimal reconstruction dictates the restoration of soft tissues in addition to hard tissues to achieve prime functional results. Regional flaps usually used for the reconstruction of such defects were considered as either bulky or none bone bearing flaps. Furthermore, using free flaps for reconstruction can rise the concerns of increased intraoperative complications and greater suspected donor site morbidities. Here we present three unfavorably previously operated patients with current huge alveolar cleft palates, planned for the reconstruction with reverse facial-submental artery osteomyocutaneous flap. Besides, detailed flap harvesting technique, results, prosthetic restoration post to flap surgery, and follow up are presented in this article. We found the reverse facial- submental osteomyocutaneous flap as a novel and reliable choice for functional reconstruction of challenging huge alveolar cleft palates. The reverse facial-submental flap has not been yet mentioned in the medical literature for the reconstruction of alveolar clefts.

## KEYWORDS

Osteomyocutaneous; Cleft; Submental flap

## Please cite this paper as:

Gholami M, Shams A, Ghadirimoghaddam N, Khalife H. Reverse Facial-Submental Artery Osteomyocutaneous Flap, a Novel Choice for Previously Operated Huge Alveolar Clefts. *World J Plast Surg.* 2022;11(3):109-115.  
doi: 10.52547/wjps.11.3.109

## INTRODUCTION

Alveolar cleft repair is considered a critical step in the management of cleft lip and palate patients. The first description for alveolar grafting was in 1901<sup>1</sup> whereas detailed procedure was then explained in the 1960s<sup>2</sup>. Moreover, the most common technique used nowadays was demonstrated in the 1970s by Boyne and Sands<sup>3</sup>. Obviously, alveolar cleft repair involves both closures of the oronasal fistula and reconstruction of the alveolus with bone graft interposed between the nasal and oral mucosal layers.

Successful alveolar cleft repair requires mobilization and tension-free closure of nasal and oral mucosal flaps. Complete graft coverage is critical to the success of the graft and in most cases is accomplished by the advancement of a keratinized buccal mucoperiosteal flap from the lesser (cleft side) maxillary segment<sup>4</sup>.

An ideal reconstructive technique for the rehabilitation of alveolar and

## \*Corresponding Author:

Abdolrahim Shams

Oral and Maxillofacial Disease Research Center, Mashhad University of Medical Science, Mashhad, Iran

Tel.: +98935 3595635

Email: [rahim.sh05@gmail.com](mailto:rahim.sh05@gmail.com)

Received: 2022/08/06

Accepted: 2022/11/11



This work is licensed under a Creative Commons Attribution-NonCommercial 4.0 International license (<https://creativecommons.org/licenses/by-nc/4.0/>). Non-commercial uses of the work are permitted, provided the original work is properly cited.

palatal defects is one that can achieve permanent separation of the oral, antral and nasal cavities without functional restoration being overlooked. An assortment of intraoral flaps have been described for the reconstruction of alveolar and palatal defects<sup>5</sup>. However, these flaps have major limitations regarding hard tissue reconstruction and considered inadequate for defects greater than one-third of the palate<sup>6</sup>. Furthermore, regional flaps were often regarded as being bulky without restoring hard tissue either. As far as soft free flaps are concerned, the radial forearm free flap is considered as an appropriate choice for palatal and alveolar reconstruction for being thin, pliable with minimal discomfort for patients wearing dentures<sup>7</sup>. However, several disadvantages concerning these flaps have been reported, particularly regarding donor site morbidity<sup>8,9</sup>.

The submental flap, based on an axial blood supply of the submental artery and vein, was first introduced by Martin et al in 1993<sup>10</sup>. Moreover, the reverse flow modification of this flap is regarded as considerable for the reconstruction of the mid-face region<sup>11</sup>. Furthermore, this flap can be harvested as an osteomyocutaneous flap; so that it can be utilized for the reconstruction of hard tissue defects at the maxillary region<sup>12</sup>.

This flap, referring to the medical literature, was not used as an osteomyocutaneous flap for the closure of alveolar cleft defects.

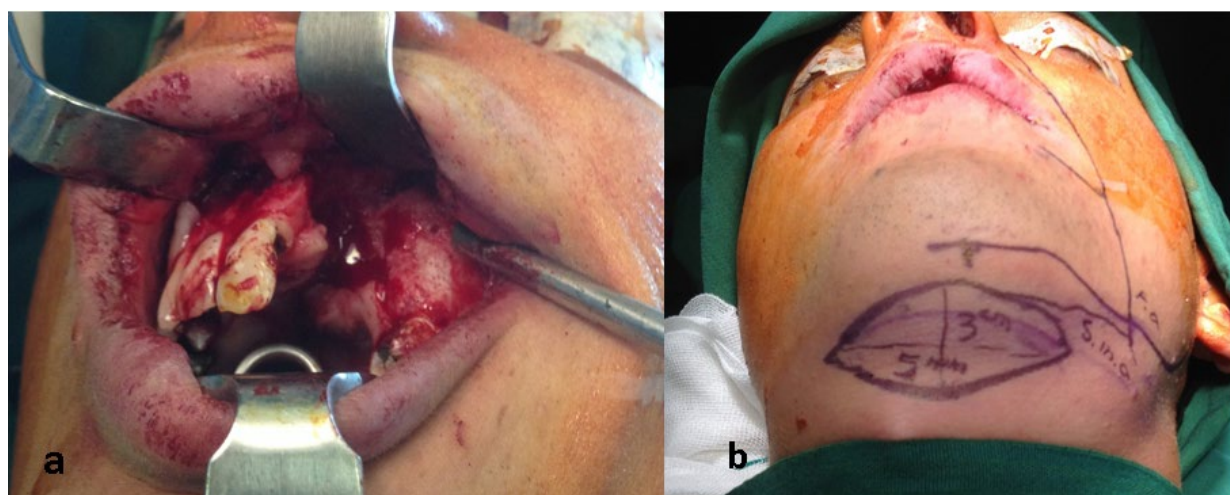
In fact, we present the reverse facial – submental artery osteomyocutaneous flap in this article as a

convenient and a novel choice for the reconstruction of huge alveolar cleft palate defects.

## TECHNIQUE

The submental island flap is supplied by the submental artery and vein; branches of the facial artery and vein respectively<sup>10,13</sup>. The submental artery arises from the facial artery and travels over the upper portion of the submandibular gland in an anterior direction. The point of its branching from the facial artery is usually after that vessel emerges from its intra-glandular course on the superior surface of the submandibular gland. After running anteriorly in a groove on the upper surface of the gland, the submental artery continues forward on the surface of the mylohyoid muscle. A detailed description of the submental anatomy can be found in Martin et al's original publication<sup>10</sup>.

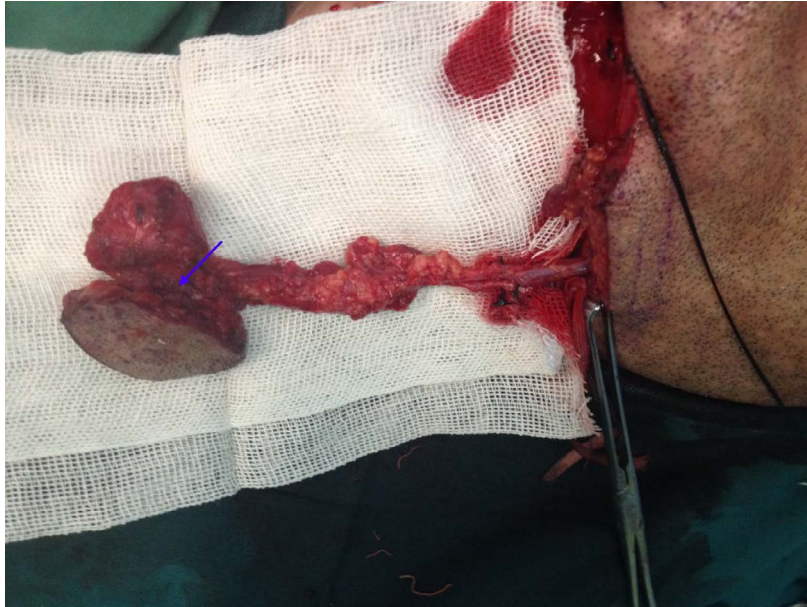The patient is positioned supinely with the head extended. Moreover, the flap is usually designed based on the size of the defect (Figure 1). Even though the maximum dimension that can be consistently harvested is 15 × 7 cm<sup>10</sup>, this must be adapted to each patient minding the laxity that indicates the amount of skin that can be harvested for primary closure. Unrelated to the flap size, the skin paddle should be designed as an ellipse to facilitate primary closure. Bearing in mind that several harvesting techniques have been reported<sup>10,14</sup>, dissection usually is started distally in the subplatysmal plane elevating the skin paddle. Dissection then proceeds to the origin of the



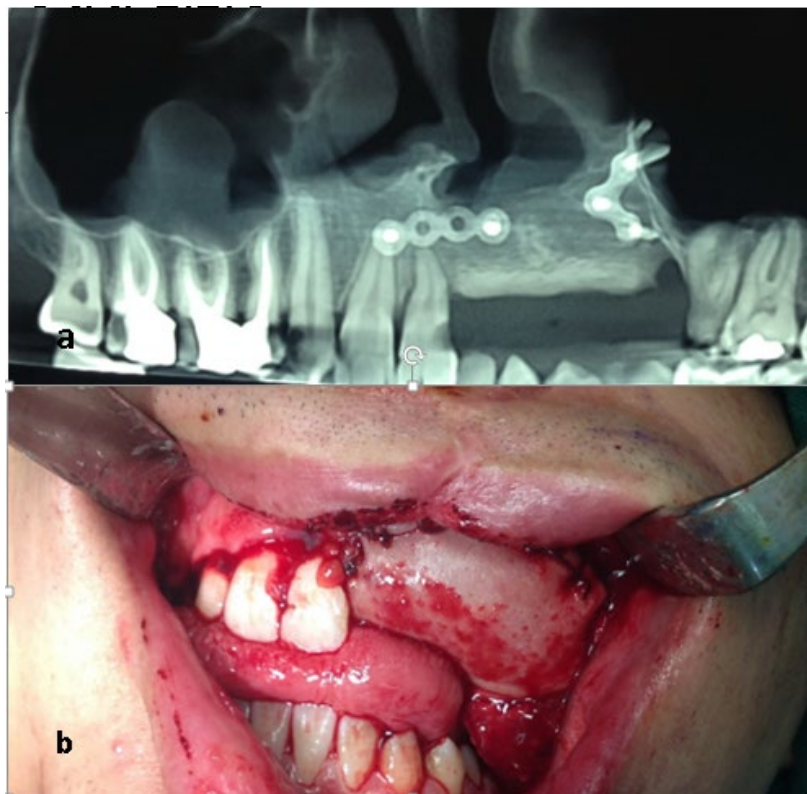
**Figure 1:** (a) Preparation of the recipient site (b) Dimensions of flap needed to be harvested

pedicle, where the submental vessels are identified and the anterior belly of the digastric muscle ipsilateral to the vascular pedicle is incorporated in the flap. The anterior belly of the digastric muscle with the periosteum at the symphysis site, where the hard tissue is supposed to be harvested, will

remain attached to the bone that will be bi-cortically harvested suiting the defect size (Figure 2). This step is indispensable to assure the vascularity of the hard tissue harvested. In the next step, branches of the submental vessels to the submandibular gland are ligated and deep fascial attachments are set free.



**Figure 2:** Osteomyocutaneous submental flap harvested, note the anterior belly of digastric muscle (blue arrow)



**Figure 3:** (a) The flap is fixed at the recipient site (b) Bone fixed with mini-plates and screws

When the superior incision of the flap is carried out, the marginal mandibular branch of the facial nerve is located and preserved. The dissection proceeds so that the flap can easily reach the distal edge of the palatal defect without tension.

A tunnel, in the subcutaneous plane, close to the palatal defect at the superior aspect of the submandibular incision is created. The osteomyocutaneous paddle is then carefully passed through the tunnel into the oral cavity.

Mini or microplates are then used to fix hard tissue part of the flap to the maxilla at the site of the defect (recipient site) (Figure 3). Absorbable sutures are used to secure the submental skin into the palatal soft tissue defect. The mandibular defect post to harvesting was reconstructed with titanium mesh and fixed with mini screws (Figure 4). The donor site defect is closed primarily by undermining of the inferior skin flaps and advancing these flaps to attain a primary closure. Passive drains, in the donor site and the subcutaneous tunnel, are placed to prevent hematoma.

## PRESENTATION OF CASES

This study was approved by the Institutional Human Research and Ethics Committee of Quaem Hospital-

Mashhad (Ethical approval IR.mums.sd.Rec.1395). Moreover, Helsinki Declaration guidelines were respected in this investigation.

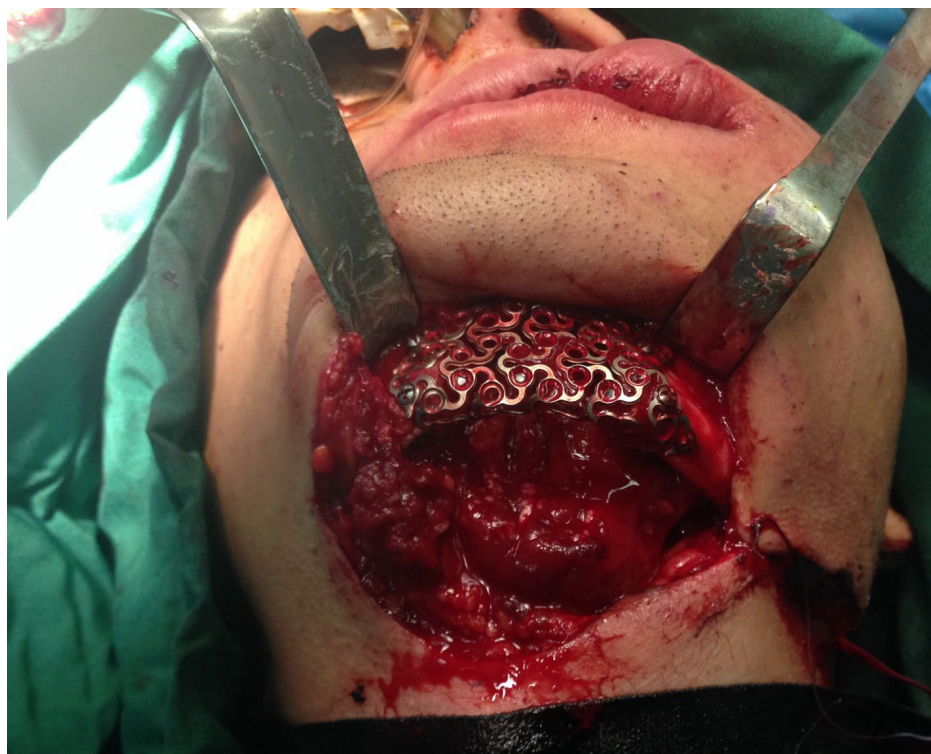Three adult white male patients with huge alveolar clefts were presented for evaluation and treatment. Patients' ages were 19, 25 and 35 years old. These patients suffered from unilateral cleft lip and palate, where the lip and palate were treated at infancy. However, the alveolar cleft was inappropriately approached in these patients; presenting failure with huge oroantral communication as an outcome.

The three patients were non-smokers with no history of systemic diseases.

Bearing in mind the surgical technique mentioned earlier, the recipient site, as usual, was first prepared during surgery, so that soft and hard tissue defects to be reconstructed can be evaluated.

Post to recipient site preparation, flap harvesting is initiated; where hard tissue from the mandibular symphysis's border is incorporated in the reversed flow submental flap.

The dimensions of hard tissue harvested from the mandibular symphysis's border in the three patients ranged from 3\*1.4 cm (width\*height) to 4.5\* 2 cm. On the other hand, soft tissue dimensions of the submental flap harvested ranged from 4\*2.5cm to 5.5\*3.5 cm according to the defect size.



**Figure 4:** the mandibular defect is reconstructed with titanium mesh

Moreover, 3 weeks post to surgery, deepithelialization of the flap took place to prevent the regrowth of facial hair intraorally. Two of the patients had implant surgery 6 weeks postoperatively (2 implants each) (Figure 5), while the third patient preferred a

partial denture for financial purposes. Implant loading prosthesis was delivered to the two patients about the 3-month post to healing. Finally, the three patients were followed up till 2-3 years after surgery.

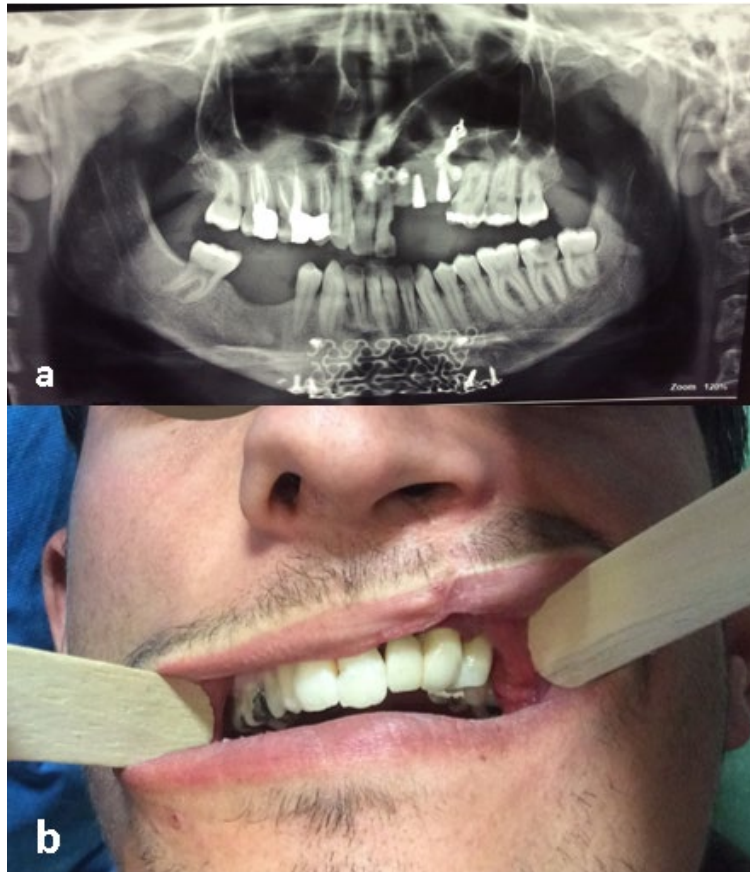


Figure 5: (a) Placement of implants 6 weeks postoperatively (b) Loading of the implants 3 months later

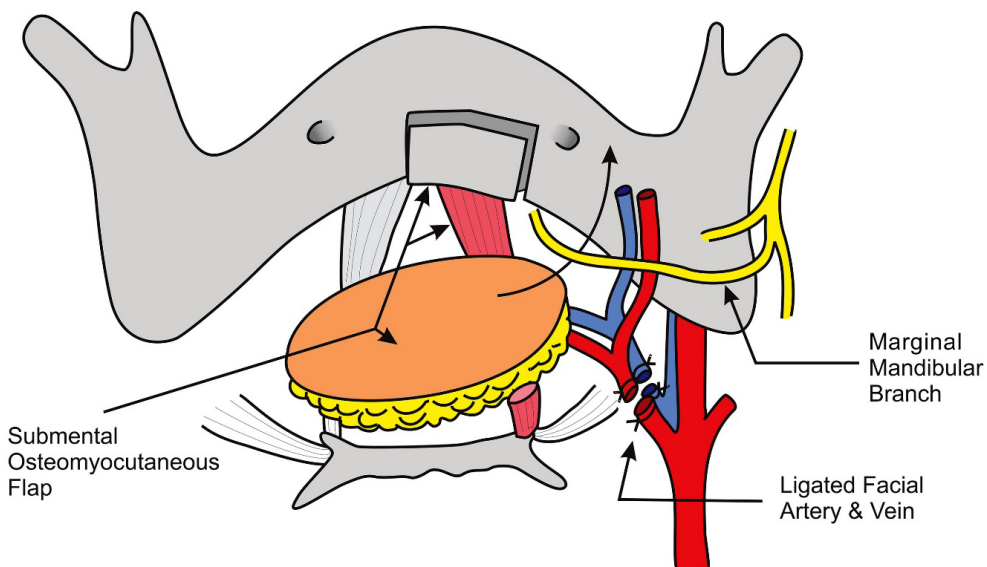


Figure 6: schematic diagram of Reverse facial-submental artery osteomyocutaneous flap

## DISCUSSION

Reconstruction of alveolar clefts has always been a challenging issue. Moreover, huge sized clefts with a history of previous operations can be more puzzling in such cases. Reconstruction of the alveolar clefts or hard palate requires obviously the separation of the oro-nasal and oroantral communications for functional and esthetic reasons. The sealing of such communications solely with soft tissue flaps without the reconstruction of hard tissues does not fulfill the objective of optimal reconstruction. Furthermore, microsurgical techniques can have limitations for elderly patients, patients with systemic, donor site morbidity, and patients who have undergone previous operations with depleted recipient vessels<sup>15</sup>. The reverse flow osteomyocutaneous submental flap was used successfully by several authors for post ablative purposes in the midface region<sup>15, 16</sup>. However, the use of this flap in alveolar/ cleft palate reconstruction was not previously mentioned in the medical literature. For this reason, the authors of this article introduced the usage of this flap for the reconstruction of huge sized alveolar and palatal defects post in non-successful previously operated patients.

The skin paddle of the osteomyocutaneous submental flap can be harvested up to 7\*18 cm<sup>10</sup>, while the bone tissue carried escorting this flap can be up to 2\*10 cm<sup>17</sup>.

The mean harvested skin paddle of the applied flaps in this article was 4.75\*3 cm. whereas the bone tissues escorting these flaps had a mean of 3.75\*1.7 cm.

The ipsilateral anterior belly of the digastric muscle was included in the harvested flaps of the three cases reported in this article. Bearing in mind the variable point of origin of the perforators, and the variable relationship of the submental artery to the anterior belly of the digastric muscle; it would seem judicious to harvest the anterior belly of the digastric muscle with this flap to warrant the capture of the dominant blood supply to the overlying skin<sup>18</sup>. Besides, the presence of the anterior belly of the digastric muscle can also be rationalized for the sake of preventing venous congestion of the harvested flap<sup>19</sup>.

The mylohyoid muscle was not incorporated in the harvested flaps reported in this article to avoid flap bulkiness. Moreover, Urken et al reported that the

submental flap could be safely harvested without incorporating the mylohyoid muscle as long as the surgeon adheres to the strategy of including the anterior belly of the digastric muscle<sup>18</sup>.

The osteomyocutaneous submental flaps were deepithelialized in the three patients introduced in this article 3 weeks after surgery. The purpose of this deepithelialization was to prevent the regrowth of the intraoral hair<sup>20</sup> and to obtain a less bulky soft tissue coverage over the desired implant sites.

Moreover, deepithelialization of the submental flap was first introduced in 1997<sup>12</sup> and is recently being applied throughout harvesting, when indicated, without the fear of jeopardizing the vascularity of the submental flap<sup>21</sup>.

Two of our patients had implant surgery 6 weeks postoperatively (2 implants each), where 4.1\*11 mm implants were applied to the harvested bone tissues. Moreover, loading of the implants took place 3-month post to the implant surgery. The follow-up of these patients for 3 years postoperatively showed no implant failure.

Chen et al reported the use of reverse osteomyocutaneous submental flap; placing 21 dental implant fixtures at the time of flap harvesting in 5 maxillary post ablative defects simultaneously<sup>19</sup>. It was noted that only one implant was lost before loading, whereas the 20 other implants were loaded successfully. Actually, the bone tissue of the harvested osteomyocutaneous submental flap can be identified as reliable for implant placement simultaneously or postoperatively.

As far as donor site morbidity of the submental flap is concerned, reports have recognized it to be minimal<sup>16</sup>. Injury to the marginal mandibular nerve can be the most potential risk related to submental flap harvesting. However, this complication is best sidestepped by the initial identification of this nerve; soon after completing the upper incision of the flap at the beginning of the harvesting<sup>18</sup>.

Moreover, neither esthetic nor functional significant donor site consequences were noted post to submental flap harvesting in the three cases presented in this article.

## CONCLUSION

The reverse facial- submental osteomyocutaneous flap is a safe alternative flap for repairing huge alveolar clefts defects with minimal donor site

morbidity. This flap can be considered as a novel and reliable choice for functional reconstruction of challenging huge alveolar cleft palates.

## FUNDING

None.

## CONFLICT OF INTEREST

None.

## REFERENCES

1. Koberg WR. Present view on bone grafting in cleft palate (a review of the literature). *J Maxillofac Surg* 1973 //;1:185-93.
2. Backdahl M, Nordinke. Replacement of the maxillary bone defect in cleft palate. A new procedure. *Acta Chir Scand* 1961 Sep;122:131-7.
3. Boyne PJ, Sands NR. Secondary bone grafting of residual alveolar and palatal clefts. *J Oral Surg* 1972 Feb;30(2):87-92.
4. Kazemi A, Stearns JW, Fonseca RJ. Secondary grafting in the alveolar cleft patient. *Oral Maxillofac Surg Clin North Am* 2002 11//;14(4):477-90.
5. Komisar A, Lawson W. A compendium of intraoral flaps. *Head Neck Surg* 1985 Nov-Dec;8(2):91-9.
6. Okay DJ, Genden E, Buchbinder D, Urken M. Prosthodontic guidelines for surgical reconstruction of the maxilla: a classification system of defects. *J Prosthet Dent* 2001 Oct;86(4):352-63.
7. Hatoko M, Harashina T, Inoue T, Tanaka I, Imai K. Reconstruction of palate with radial forearm flap; a report of 3 cases. *Br J Plast Surg* 1990/05/01;43(3):350-4.
8. Riecke B, Kohlmeier C, Assaf AT, et al. Prospective biomechanical evaluation of donor site morbidity after radial forearm free flap. *Br J Oral Maxillofac Surg* 2016 2//;54(2):181-6.
9. Pohlenz P, Klatt J, Schön G, Blessmann M, Li L, Schmelzle R. Microvascular free flaps in head and neck surgery: complications and outcome of 1000 flaps. *Int J Oral Maxillofac Surg* 2012 6//;41(6):739-43.
10. Martin D, Pascal JF, Baudet J, et al. The submental island flap: a new donor site. Anatomy and clinical applications as a free or pedicled flap. *Plast Reconstr Surg* 1993 Oct;92(5):867-73.
11. Faltaous AA, Yetman RJ. The submental artery flap: an anatomic study. *Plast Reconstr Surg* 1996 Jan;97(1):56-60; discussion 1-2.
12. Yilmaz M, Menderes A, Barutcu A. Submental artery island flap for reconstruction of the lower and mid face. *Ann Plast Surg* 1997 Jul;39(1):30-5.
13. Whetzel TP, Mathes SJ. Arterial anatomy of the face: an analysis of vascular territories and perforating cutaneous vessels. *Plast Reconstr Surg* 1992 Apr;89(4):591-603; discussion 4-5.
14. Vural E, Suen JY. The submental island flap in head and neck reconstruction. *Head Neck* 2000 Sep;22(6):572-8.
15. Chen WL, Ye JT, Yang ZH, Huang ZQ, Zhang DM, Wang K. Reverse facial artery-submental artery mandibular osteomuscular flap for the reconstruction of maxillary defects following the removal of benign tumors. *Head Neck* 2009;31(6):725-31.
16. Ducic Y. Hard palate reconstruction with a pedicled osteomyocutaneous mandible flap: case report. *J Oral Maxillofac Surg* 2001;59(11):1355-8.
17. Blondeel PN, Morris SF, Hallock GG, Neligan PC. Perforator flaps: anatomy, technique, & clinical applications. CRC Press; 2013. p. 161.
18. Urken ML, Cheney ML, Blackwell KE, Harris JR, Hadlock TA, Futran N. Atlas of regional and free flaps for head and neck reconstruction: flap harvest and inseting. Lippincott Williams & Wilkins; 2012. p. 109.
19. Chen W-l, Zhou M, Ye J-t, Yang Z-h, Zhang D-m. Maxillary functional reconstruction using a reverse facial artery-submental artery mandibular osteomuscular flap with dental implants. *J Oral Maxillofac Surg* 2011;69(11):2909-14.
20. Rahpeyma A, Khajehahmadi S. Oral reconstruction with submental flap. *Annals of Maxillofacial Surgery* 2013 Jul-Dec;3(2):144-7.
21. Tan O, Atik B, Parmaksizoglu D. Soft-tissue augmentation of the middle and lower face using the deepithelialized submental flap. *Plast Reconstr Surg* 2007;119(3):873-9.